

A CHALLENGING SITUATION- PREGNANCY, PTMC, PLACENTA PREVIA PERCRETA

Asma Ansari¹, Imran Fazal², Ambreen Anwer³, Ghulam Abbas⁴

^{1,2,4} Armed Forces Institute of Cardiology & National Institute of Heart Diseases, Rawalpindi, Pakistan
³ Military Hospital Rawalpindi, Pakistan

Address for Correspondence:

Dr. Asma Ansari,

Armed Forces Institute of Cardiology & National Institute of Heart Diseases, Rawalpindi, Pakistan

Email: asmaansari31@gmail.com

Date Received: January 08, 2014

Date Revised: February 28, 2015

Date Accepted: April 10, 2015

Contribution

All the authors contributed significantly to the research that resulted in the submitted manuscript.

All authors declare no conflict of interest.

This article may be cited as: Ansari A, Fazal I, Anwer A, Abbas G. A challenging situation - pregnancy, ptmc, placenta previa percreta. Pak Heart J 2015;48(3): 166 - 169.

ABSTRACT

Cardiac disease is a leading cause of maternal mortality worldwide. Mitral stenosis is the most common form with increased pregnancy and delivery complications for both mother and neonate. During pregnancy physiological hemodynamic changes of the circulation are the main cause of mitral stenosis decompensation. Morbidly adherent placenta is a serious complication of pregnancy and is associated with massive intrapartum hemorrhage and high maternal morbidity and mortality. The case under discussion is of a recently diagnosed patient with severe mitral stenosis and placenta previa who was effectively managed in a tertiary care setting inspite of having both cardiac and obstetric life threatening situations with a outcome comparable to a normal patient.

Key Words: Percutaneous Transmural Commissurotomy , Placenta praevia , ultrasonography, pregnancy.

INTRODUCTION

Valvular heart diseases complicates about 0.5- 1% of all pregnancies.¹ The symptoms are poorly tolerated especially beyond second trimester and in some cases may lead to frank heart failure. Most pregnant women with mitral stenosis can be adequately treated with medical therapy but sometimes an invasive procedure is mandatory.² Before the introduction of percutaneous transluminal mitral commissurotomy (PTMC) in 1984, surgical mitral valve commissurotomy (MVC) was the sole answer to pregnant women with refractory symptoms.³ The high mortality rate (1.8% to 33%) of surgery and favorable outcome of PTMC in relieving symptoms plus lower risk of fetal complications has proved PTMC a safe procedure with outstanding results.⁴ In placenta previa (PP), the placenta is located over or very near the internal cervical Os. Maternal and fetal morbidity and mortality from PP are considerable, and associated with high demands on health care resources. Given the rising incidence of cesarean section, the number of cases of PP and its complications, including placenta accreta (PA), increta and percreta, different grades of placental adherence because of abnormal development of deciduas basalis will continue to increase.⁵ Surgery for morbidly adherent placenta is a considerable challenge, but it has been reported that

Table 1: Pre and Post PTMC Echo Findings

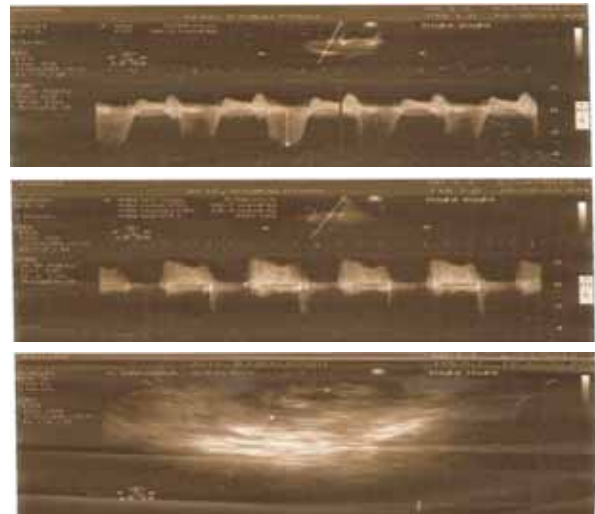
Echo findings	Pre procedure	Post procedure
Mitral valve area	0.8 cm ²	2.0 cm ²
Aortic root diameter	25	26
Left ventricle systolic diameter	20	26
Left Ventricle diastolic diameter	35	46
Mean pressure gradient (MPG)	21	5
Pulmonary artery systolic pressure(PASP)	70 mm Hg + CVP	30mmHg + CVP

maternal morbidity is reduced in women who deliver in a tertiary care hospital with a multidisciplinary care team and we present this situation in this case report.⁶

CASE REPORT

A 28 year old lady G3P2, previous two cesarean sections, at 32 weeks was referred from a peripheral hospital, with newly diagnosed severe mitral stenosis(Mitral valve area < 1.5cm²) and pulmonary hypertension. She had a warning hemorrhage at 28 weeks of gestation after which she was diagnosed as placenta previa on ultrasound. She had cough and shortness of breath since one month which aggravated resulting in severe limitation of physical activity (NYHA III). She had no significant past, drug, family or occupational history. On examination she had BMI of 23 Kg/m², blood pressure 100/70 mm of Hg and pulse 100/min. There was no cyanosis, pallor, clubbing or

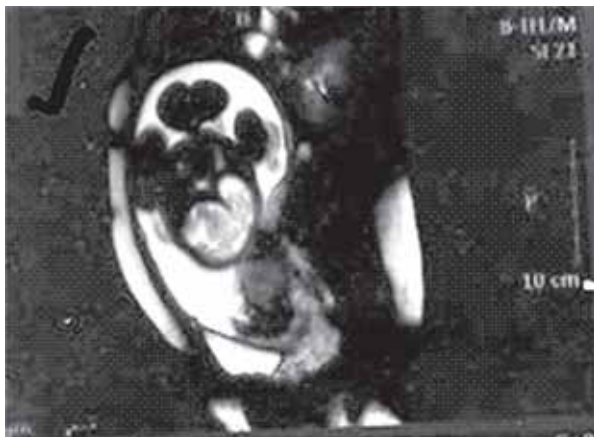
Figure 1: Echocardiography Findings



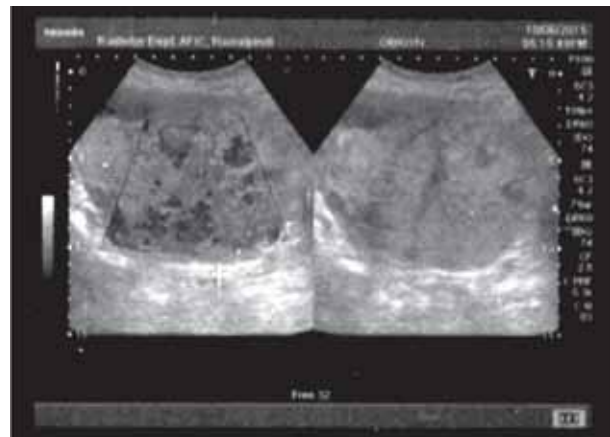
lymphadenopathy. Her cardiovascular system examination revealed a mid diastolic loud rumbling murmur at the apex heard best in left lateral position. On obstetrical examination fundal height was corresponding to dates, presenting part was high and unengaged.

Her laboratory tests revealed, Hb of 10.7g/dl. Rest of investigations were normal. Echocardiogram showed dilated left atrium, right atrium and severe mitral stenosis (MVA < 1.0cm²)(Figure 1). Transesophageal Echo(TOE) showed no clot or pericardial effusion. Electrocardiogram (ECG) showed sinus rhythm. Repeat ultrasonography at 34 weeks suggested placenta previa type IV with suspicion of accreta (Figure 2 a). On surface echo Wilkins criteria was met for PTMC and contraindications to procedure were excluded on TOE. PTMC was done with 26 mm inoue balloon and abdominal shielding to minimize radiation exposure to fetus. Procedure was done through femoral approach and mitral valve dilated. Patient was nursed in post

Figure 2 a: MRI Showing Indistinct Interface of Placenta with Surrounding Structures. b: USG Showing Placental Implantation and Large Sinuses on Lower Segment



a



b

cath ward. There was dramatic improvement in her symptoms immediately after procedure. Pre and post procedure echo findings are shown in figure 1.

After stabilization her MRI was done to rule out morbidly adherent placenta which suggested placenta percreta with possible invasion into urinary bladder anteriorly and sigmoid colon posteriorly as shown in figure 2 b. Multidisciplinary meeting with obstetrician, cardiologist, cardiac anesthetist, urologist, colorectal surgeon and hematologist was held. Caesarean section was planned at 36 weeks with institutional protocol for operating placenta previa. High risk consent taken, blood and blood products arranged, surgery performed by consultant, upper segment uterine incision used to reduce blood loss, internal iliac artery ligation to control homeostasis on requirement if needed. Considering her MRI findings consent for prolonged catheterization in event of bladder involvement and colostomy in case of colon involvement was taken. General anesthesia was given and invasive monitoring done in a fully equipped cardiac theatre. A 2.8 kg baby girl was delivered as breech. Placenta was morbidly adherent so immediate decision to perform obstetric hysterectomy was taken. Placenta was invading the bladder but mucosa was spared. Bladder was carefully dissected and bleeding controlled. There was no intestinal involvement. She was transfused three units RCC during procedure. Her immediate postoperative course was uneventful and intensive care stay was two days. She was discharged with a healthy neonate on fifth post operative day. On subsequent follow up visit she had no cardiac or obstetric complications.

DISCUSSION

Pregnancy is characterized by a hyper dynamic state with significant hemodynamic changes especially between 24 and 32 week of gestation and can explain de compensation in pregnant women with critical mitral stenosis. In some cases, maximal clinical therapy is not enough and an invasive intervention is required.³ In a study, percutaneous balloon dilation of the mitral valve had a success rate of 95%, as demonstrated by the final mitral valve area achieved. This improvement was followed by a marked decrease in the mitral valve gradient, left atrial pressure and mean pulmonary artery pressure. The patients who underwent percutaneous balloon dilation had significantly fewer fetal and maternal complications, compared with open MVC during pregnancy.⁷ The incidence of placenta previa is 1%. The major morbidity associated with an abnormal placentation primarily arises from significant blood loss that occurs at the time of delivery, requiring longer maternal hospital stay and blood transfusion. In addition, pregnancies complicated by placenta accreta are associated with increased incidence of cystotomy, ureteral injury, pulmonary embolism, need for ventilatory support, re-operation, and intensive care unit (ICU) admission.⁸ It has

been noted that one prior CS delivery doubles the risk of placenta previa in a subsequent pregnancy and these women are particularly at risk for different grades of placental adherence like accrete, increta and percreta in which placenta invades through the uterine wall into surrounding structures. Abnormal placental adherence to/or invasion into the myometrium prevents normal separation of the placenta at the time of delivery, potentially resulting in life-threatening uterine hemorrhage or retained products of conception.⁴ USG and MRI show no significant difference in sensitivity and specificity in diagnosing abnormal placentation (97-100% and 94-100%, respectively). MRI is more sensitive than USG for the detection of myometrial invasion and the type of abnormal placentation (73.5% and 47%, respectively) like increta and percreta.⁹ So an early and systematic detection of abnormal placentation is a crucial step in planning delivery and subsequent management to overcome the associated morbidity.¹⁰

CONCLUSION

This was a unique combination of obstetric and cardiac life threatening conditions in one patient nevertheless we emphasize the need for multidisciplinary approach to handle these patients for a better outcome.

REFERENCES

1. Abidi S, Salehi N, Ghodsi B, Basiri H, Momtahn M, Firouzi A, et al. Immediate results of percutaneous transluminal mitral commissurotomy in pregnant woman with severe mitral stenosis. *Clin Med Insights Cardiol* 2012;6:35-9.
2. Glantz JC, Pomerantz RM, Cunningham MJ, Woods JR. Percutaneous balloon valvuloplasty for severe mitral stenosis during pregnancy: a review of therapeutic options. *Obstet Gynecol Surv* 1993;48:503-8.
3. Wong MC, Clark DJ, Horrigan MC, Grube E, Matalanis G, Farouque HM. Advances in percutaneous treatment for adult valvular heart disease. *Intern Med J* 2009;39:465-74.
4. Desouza J, Martinez E, Ambrose J, Alves C, Born D, Buffolo E, et al. Percutaneous balloon mitral valvuloplasty in comparison with open mitral valve commissurotomy for mitral stenosis during pregnancy. *J Am Coll Cardiol* 2001;37:900-3.
5. Silver RM. The MFMU cesarean section registry: maternal morbidity associated with multiple repeat cesarean deliveries. *Obstet Gynecol* 2006;07:1226-32.
6. Warshak CR, Ramos GA, Eskander R, Benirschke K, Saenz CC, Kelly TF, et al. Effect of pre delivery diagnosis in 99 consecutive cases of placenta accreta. *Obstet*

- Gynecol 2010;115:65-9.
7. Inoue K, Owaki T, Nakamura T, Kitamura F, Miyamoto N. Clinical application of transvenous mitral commissurotomy by a new balloon catheter. *J Thorac Cardiovasc Surg* 1984;87:394-402.
 8. Kassem J, Alzahrani A. Maternal and neonatal outcomes of placenta previa and placenta accrete: three year of experience with a two consultant approach. *Int J Womens Health* 2013;5:803-10.
 9. Allgebally A, Yousaf R, Badr S, Obeidly A, Szmigłowski W, Allbrahim A. The value of ultrasound and magnetic resonance imaging in diagnostics and prediction of morbidity in cases of placenta previa with abnormal placentation. *Pol J Radiol* 2014;79:409-16.
 10. Eller AG, Bennett MA, Sharshiner M, Masheter C, Soisson AP, Dodson M, et al. Maternal morbidity in cases of placenta accreta managed by multidisciplinary care team compared with standard obstetric care. *Obstet Gynecol* 2011;117:331-7.