

PREVALENCE OF ISCHEMIC HEART DISEASE IN OUR LOCAL COMMUNITY USING NONINVASIVE 2-D ECHOCARDIOGRAPHIC APPROACH

Aman Ullah Saleh¹, Syed Talha Shah², Syed Saadat Ali³, Shahid Zaman⁴

^{1,3-4} Baqai Institute of Cardiovascular Diseases, Karachi, Pakistan

² Ziauddin University, Karachi, Pakistan

Address for Correspondence:

Dr. Aman Ullah Saleh,

Baqai Institute of Cardiovascular Diseases, Karachi, Pakistan

E-Mail: saleh.amanullah@gmail.com

Date Received: December 06, 2014

Date Revised: March 17, 2015

Date Accepted: April 27, 2015

Contribution

All the authors contributed significantly to the research that resulted in the submitted manuscript.

All authors declare no conflict of interest.

This article may be cited as: Saleh AU, Shah ST, Ali SS, Zaman S. Prevalence of ischemic heart disease in our local community using noninvasive 2-d echocardiographic approach. Pak Heart J 2015;(3): 153 - 157.

ABSTRACT

Objective: To study the prevalence of ischemic heart disease in our local community using noninvasive 2-D Echocardiographic approach.

Methodology: This cross sectional observational study was conducted from January 2011 to August 2011 in the Radiology department (Echocardiography Section) of Memon Medical Institute hospital Karachi. Cases included both genders with no age limitations, diagnosed with Transthoracic Echocardiography.

Results: Among 418 patients, (49%) were males with mean age of 56.1 years. Wall Motion Abnormality (WMA) was present in 27.99%. Every 3rd among male cases had WMA while every 4th among female cases had WMA. Majority (58.97%) of patients with WMA were found in 51-70 years age group. The Left Anterior Descending (LAD) artery territory is found to be the most frequently affected.

Conclusions: Males of middle to old age group are vulnerable to coronary artery disease and the most frequent involvement is Left Anterior Descending artery. The presence of regional wall motion abnormality necessitates further investigation to minimize later complication of coronary artery disease.

Key Words: Prevalence, Ischemic Heart Disease, Echocardiography, Wall Motion Abnormality

INTRODUCTION

Regional Wall motion abnormalities (RWMA) can be visualized through echocardiography within seconds of a coronary artery occlusion, and occurs prior to the onset of electrocardiographic changes or the development of symptoms.^{1,2} RWMA are detected as a localized decrease in rate & amplitude of myocardial excursion and may develop prior to symptoms. The presence of RWMA does not establish the diagnosis of ischemia. There are numerous other reasons for RWMA like non-ischemic cardiomyopathy, focal myocarditis, right ventricular volume overload, ventricular pre-excitation, Wolff-Parkinson-White syndrome and left bundle branch block and others. Therefore these abnormalities should be excluded before diagnosing WMA as ischemic in origin.

For the purpose of localizing segmental wall motion abnormalities in a standardized format, the American Heart Association (AHA), as part of an effort to unify wall motion analysis among different imaging modalities, has recommended a seventeen segment model.³

The different Echocardiographic views permit visualization of regions of the myocardium perfused by the different coronary artery branches:

Anteroapical wall - Involvement of the septum, apex, and anteroapical regions of the left ventricle are typical sites of occlusion in left anterior descending artery circulation; they are best seen in the parasternal long axis and apical two or four chamber views. Inferobasal wall - Inferior infarctions usually arise from occlusion of the right coronary artery and occasionally from occlusion of a posterior descending branch arising from the circumflex artery in a left dominant system. These wall motion abnormalities are well seen in the short axis but even better by using the apical two chamber view with a slight degree of posterior tilt.

Lateral or free wall - the left ventricular free wall is a less common site for isolated MI; though the lateral wall may become akinetic in circumflex artery occlusion, the lateral wall is more frequently involved as a component of multi-segmental involvement. Left main disease may cause anterior, lateral, and apical wall motion abnormalities, and left anterior descending artery disease may involve the entire apex, including the lateral apex. The base of the free wall is the least likely site of an ischemic Echocardiographic abnormality.

Right ventricle - Obstruction of the proximal right coronary artery proximal to the right ventricular marginal branches may infarct the right ventricle and the inferior wall of the left ventricle. Some studies suggest that as many as 40 percent of inferior infarctions are complicated by some degree of right ventricular dysfunction. However, there is a major difference between mild subclinical depression of right

ventricular contractile function, which is associated with subtle Echocardiographic abnormalities, and severe impairment of right ventricular performance, which can lead to hypotension or shock, due to reduced left ventricular preload. But in this study we have only considered the Left Ventricular wall motion abnormality.

For aiming at diagnosis and treatment, we need to have some idea of the prevalence of the disease. There isn't much data available, on this topic, from our population. Therefore, our study aims to probe the frequency of WMA and so the burden (both acute and chronic cases) of CAD in our population and to find its relationship with the age and gender by using a noninvasive Echocardiographic approach.

METHODOLOGY

This cross sectional observational study was conducted in the radiology department (Echocardiography section) of Memon Medical Institute Hospital, Karachi, Pakistan. The study was conducted from January 2011 to August 2011. Cases includes both genders with no age limitations, diagnosed with segmental wall motion abnormality on Transthoracic Echocardiography.

Patients with prior surgery, focal myocarditis, right ventricular volume overload, Wolff-Parkinson-White and ventricular pre-excitation, left bundle branch block or non-ischemic cardiomyopathy were excluded from the study. Data included age, gender and the findings of wall motion abnormality on 2-D Transthoracic Echocardiogram. The coronary artery territory involvement later analyzed. We used 2-D Parasternal Long axis, Parasternal Short axis, Apical four chamber and Apical two chamber views for the assessment of segmental wall motion abnormalities. Data analysis was performed using SPSS version 10.

RESULTS

This study consisted of 418 patients. About 49% were males. Mean age was found to be 56.1 years. About 27.99 % of cases were diagnosed with WMA (Figure 1). While on comparison the percentage of WMA is greater among males than among female (Figure 1) i.e. approximately every 3rd case among male subjects were having WMA while every 4th case among female subjects had this. Age is distributed in five equal groups (Table 1) and about 58.97 % of patients with WMA were belongs to 51-70 years of age group (Table-2).

On analysis of pattern of WMA according to 17-segment model, it is acknowledged that most frequently effected LV segments are mid to apical Anterior and Septal wall followed by the Inferior wall (Figure 2). On further analysis on the disease distribution of coronary arteries, it is observed that in our study Left Anterior Descending (LAD) territory is most

Table 1: Age Group Distribution

AGE GROUP (YEARS)	NUMBER OF PATIENTS (n)	PERCENTAGE OF PATIENTS (%)
11 - 30	40	9.56 %
31 - 50	84	20.09 %
51 - 70	202	48.32 %
71 - 90	88	21.05 %
>90	4	0.95 %
TOTAL	418	100 %

frequently diseased i.e. 40.34% and followed by the Left Circumflex(LCx) i.e. 30.35% (Table 3).

DISCUSSION

In the management of patients with acute myocardial infarction (MI) echocardiography is a standard tool. The role of echocardiography in establishing the diagnosis, location, and extent of MI, diagnosing mechanical complications of infarction, and providing prognostic information that is important for risk stratification have been proved.⁴

Two-dimensional (2D) echocardiography provides high-resolution images of cardiac structures and their movements and allows visualization of the endocardial border, wall motion assessment, thickening of the ventricular walls and evaluation of left ventricular systolic function. It also provides quantitative measurements of cardiac dimensions, area, and volume.

By convention, segment systolic wall thickening and endocardial inward motion are usually graded as: Normal. Hypokinetic i.e. reduced and delayed contraction. Akinetic, i.e. absence of inward motion with or without thinning or scarring. Dyskinetic, i.e. systolic thinning and outward systolic endocardial motion. Myocardial infarction often reflect by Akinesia and dyskinesia and therefore indicating

Table 2: Age Distribution of Regional Wall Motion Abnormality

AGE GROUP (YEARS)	NO. OF RWMA PATIENT (MALE)	NO. OF RWMA PATIENT (FEMALE)	TOTAL NO OF RWMA PATIENTS	% OF RWMA ACCORDING TO AGE GROUP
11 - 30	-	2	2	17 %
31 - 50	4	12	16	3.82 %
51 - 70	31	38	69	58.97 %
71 - 90	17	13	30	7.17 %
>90	1	-	-	
TOTAL	52	65	117	

WMA = wall motion abnormality

Table 3: Distribution of Coronary Artery Disease

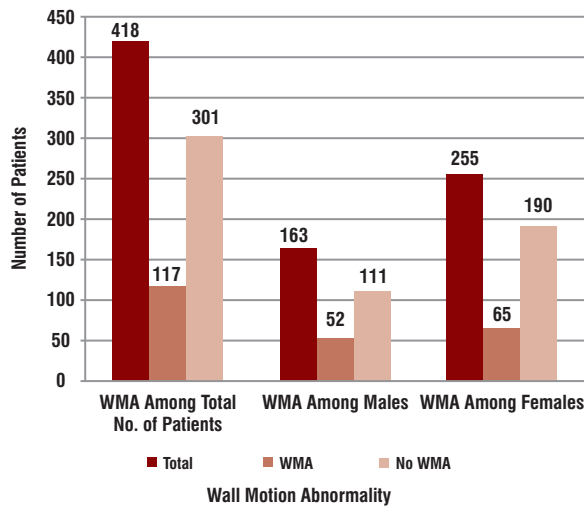
LEFT VENTRICULAR WALL SEGMENTATION ACCORDING TO CORONARY ARTERIAL DISTRIBUTION	CORONARY ARTERY SUPPLYING	PERCENT (%) OF THE ARTERIAL TERRITORY DISEASED IN OUR STUDY
Basal anterior + Mid anterior + Apical anterior + Basal anteroseptal + Mid anteroseptal + Apical septal + Apex	LEFT ANTERIOR DESCENDING (LAD)	40.34 %
Basal Anterolateral + Mid Anterolateral + Basal inferolateral + Mid inferolateral + Apical lateral	LEFT CIRCUMFLEX (LCX)	30.35 %
Basal inferoseptal + Mid inferoseptal + Basal inferior + Mid inferior + Apical inferior	RIGHT CORONARY ARTERY (RCA)	29.31 %

nonviable myocardium. Hypokinetic segments are usually viable and probably reflect hibernating myocardium.

Considering the observations that RWMAs are an early sign of myocardial ischemia and that the absence of RWMAs effectively rules out ischemia, a group of investigators prospectively studied the utility of echocardiography in the triage of patients with chest pain⁵. It was concluded that if echocardiogram showed no RWMAs, it is relative safe to discharge the patient from the emergency department while patients with RWMAs should be admitted for further observation and treatment. Those patients with a suspicious chest pain syndrome in whom an adequate echocardiogram cannot be obtained would also warrant observation.⁴ The 2003 ACC/AHA/ASE task force gave a class I recommendation to the use of echocardiography for evaluation of chest pain in patients with suspected acute myocardial ischemia, when baseline ECG and other laboratory markers are non diagnostic and when the study can be obtained during pain or within minutes after its abatement.⁶

Myocardial ischemia may or may not present with overt symptoms and signs of myocardial ischemia and electrocardiographic findings may show Q- waves or nonspecific changes. Because of these non-conclusive findings, two-dimensional (2-D) echocardiography has been extensively used to detect myocardial ischemia through regional wall motion abnormality.⁷ In another study it is concluded that the regional wall motion abnormality has a 95% predictive value for coronary disease in patients with

Figure 1: Gender Distribution of Regional Wall Motion Abnormalities (RWMA)



left ventricular dysfunction and normal LV size with a sensitivity of 83% and specificity of 57% and so RWMA may be the surrogate of such complications as congestive heart failure, arrhythmogenic discharge, or Cardiomyopathy all of which affect the life expectancy of the patient.⁸ Hence we have chosen the same modality for our study as it is found to be very authentic, noninvasive and cost effective way for the detection of the burden of established Ischemic heart disease.

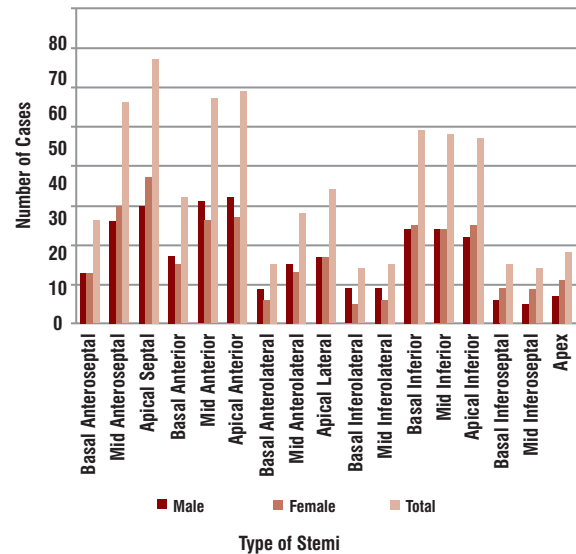
Of the total number of patients who had come for the Echocardiography test, around 28% of the patients were diagnosed with WMA. Since the subjects taken for our study were not from a sample of the general population, this frequency cannot be deemed to be the prevalence of WMA in the general population. Therefore, this is a major limitation in our study. However, this does give us an idea of the percentage of WMA cases in patients having some sort of Cardiac symptoms (for which they had been come or were referred for Echocardiography testing).

WMAs are also good predictors of coronary vessel disease. The Region (or segment) of Myocardium involved can enable us to know the blood vessel that is diseased and being responsible for the ischemia. Using 17-segment model for the detection WMA as proposed by AHA, it is concluded that in our local community.³

CONCLUSION

It is acknowledged from this study that in our community like the others, males of middle to old age group are highly vulnerable to CAD. So echocardiography should be the standard investigation in patients with suspected coronary syndromes and the presence of regional wall motion abnormality on echocardiography necessitates further investigation and management to minimize complications of

Figure 2: Frequencies of Different Regional Wall Motion Abnormalities and Their Gender Distribution



LV Segmentations are referred from 17-segment model (left bulls-eye diagram) as proposed by the AHA.

coronary artery disease.

Although the results of this study have some limitations, it forms the basis of further studies in relation to regional wall motion abnormality, coronary artery disease and prevalence of myocardial ischemia in our community.

REFERENCES

1. Hauser AM, Gangadharan V, Ramos RG, Gordon S, Timmis GC. Sequence of mechanical, electrocardiographic and clinical effects of repeated coronary occlusion in human beings: Echocardiographic observations during coronary angioplasty. *J Am Coll Cardiol* 1985;5:193-7.
2. Beller GA. Myocardial perfusion imaging for detection of silent myocardial ischemia. *Am J Cardiol* 1988;61:22F-28F.
3. Cerqueira MD. Standardized myocardial segmentation and nomenclature for tomographic imaging of the heart. A statement for healthcare professionals from the Cardiac Imaging Committee of the Council on Clinical Cardiology of the American Heart Association. *Circulation* 2002;105:539-42.
4. Cheitlin MD, Armstrong WF, Aurigemma GP, Beller GA, Bierman FZ, Davis JL, et al. ACC/AHA/ASE 2003 guideline update for the clinical application of echocardiography-summary article: a report of the American College of Cardiology/American Heart Association Task Force on Practice Guidelines (ACC/AHA/ASE Committee to Update the 1997

- Guidelines for the Clinical Application of Echocardiography). *J Am Coll Cardiol* 2003;42:954-70.
5. Sabia P, Afrookteh A, Touchstone DA, Keller MW, Esquivel L, Kaul S. Value of regional wall motion abnormality in the emergency room diagnosis of acute myocardial infarction: a prospective study using two-dimensional echocardiography. *Circulation* 1991;84:85-92.
 6. Cheitlin MD, Armstrong WF, Aurigemma GP, Beller GA, Bierman FZ, Davis JL, et al. ACC/AHA/ASE 2003 guideline update for the clinical application of echocardiography--summary article: a report of the American College of Cardiology/American Heart Association Task Force on Practice Guidelines (ACC/AHA/ASE Committee to Update the 1997 Guidelines for the Clinical Application of Echocardiography). *J Am Coll Cardiol* 2003;42:954-70. [Same as Ref no. 04]
 7. Zua MS, Potts J. Prevalence of myocardial ischemia as depicted by regional wall motion abnormality in blacks. *J Natl Med Assoc* 1996;88:444-8.
 8. Medina R, Panidis LP, Morganroth J, Kotler MN, Mintz GS. The value of echocardiographic regional wall motion abnormalities in detecting coronary artery disease in patients with or without a dilated left ventricle. *Am Heart J* 1985;109:799-802.
 9. Elhendy A, Mahoney DW, Khandheria BK, Paterick TE, Burger KN, Pellikka PA. Prognostic significance of the location of wall motion abnormalities during exercise echocardiography. *J Am Coll Cardiol* 2002;40:1623-9.