

# PATTERN OF LEFT MAIN STEM STENOSIS

Iftikhar Ahmed<sup>1</sup>, Jabbar Ali<sup>2</sup>, Muhammad Abdur Rauf<sup>3</sup>, Wahaj Aman<sup>4</sup>, Adnan Mahmood Gul<sup>5</sup>,  
 Mohammad Hafizullah<sup>6</sup>

<sup>1-6</sup>Cardiology Department, Lady Reading Hospital Peshawar, Khyber Medical University Peshawar

Address for Correspondence:

**Prof. Mohammad Hafizullah\***

Department of Cardiology,  
 Lady Reading Hospital, Peshawar -  
 Pakistan

Email: mhu5555@gmail.com

Date Received: October 20, 2012

Date Revised: December 10, 2012

Date Accepted: January 17, 2013

## Contribution

All the authors contributed significantly to the research that resulted in the submitted manuscript.

All authors declare no conflict of interest.

## ABSTRACT

**Objective:** To find out the pattern of left main stems disease in cardiology department of tertiary care hospital.

**Methodology:** This descriptive study was conducted from the properly maintained record of 3 years (January 2007 to December 2010) of cardiac catheterization lab of cardiology unit, a 1400 bedded, tertiary care hospital.

**Results:** Total numbers of cases were 3950 in which Coronary angiographies were 2058. Among them patients having normal vessels were 497 (24.14%), single vessel disease (SVD) 389 (18.9%), double vessels disease (DVD) 350 (17%), triple vessels disease (TVD) 822 (39.94%) and patients having left main stem disease were (LMS) 228 (11.03%). Mean age of the patients having LMS disease were 57.2 + 10.1 yrs. Male were 77.2%. Diabetics were 151 (66.23%). Mean LMS lesion was 50.7 % + 21 of its diameter, in which more than 50% of the segment involved were 140 (61.41%). Locations of the lesion is 4 (1.7%) proximal, 49 (21.49%) mid and 175 (76.7%) distal LMS. Presentation of patients having LMS disease was stable angina in 136 (59.64%). Numbers of coronary vessels involved were single vessels disease in 21 (9.2%), double vessels disease in 44 (19.3%) and triple vessels disease in 163 (71.5%) patients.

**Conclusion:** Left main stem disease is common angiographic finding and is associated with multivessel coronary artery disease and diabetes mellitus. It commonly occurs in distal part of vessel.

**KeyWords:** LMS (left main stem), coronary arteries, site of lesion, risk factor

## INTRODUCTION

The left main coronary artery is the most important coronary artery since it is responsible for supplying two thirds of the heart muscle with blood. Most large clinical trials have indicated that the presence of a significant narrowing in this artery is associated with a higher operative mortality. A significant LMS stenosis is considered to be a lesion occupying over 50% of the vessel diameter. Left main stem stenosis currently occurs in 4% to 6% of all patients undergoing coronary angiography<sup>1</sup> and in 30% of CABG patients<sup>2</sup>.

Left main stem stenosis is theoretically an attractive target for PCI because it is the most proximal component of the left coronary circulation and because of its relatively large diameter. However, in reality, 3 important anatomical features carry important qualifications about the likely success of PCI and CABG in LMS stenosis:

- Left main stem stenosis occurs as an isolated lesion in only 6% to 9% of patients, whereas over 70% to 80% of patients also have multivessel CAD<sup>3-10</sup>, thereby potentially enabling more complete coronary revascularization with CABG than with stenting.
- Most LMS stenoses (40% to 94%) occur in the distal segment of the artery and extend into the proximal coronary arteries<sup>3-10</sup>; such bifurcated or trifurcated lesions have a high risk of restenosis<sup>11</sup>, while acute occlusion at this site can have catastrophic consequences.
- Morphologically, around one-half of LMS lesions have significant calcification<sup>1</sup>.

The fact that most patients with LMS stenosis have bifurcation disease and simultaneous multivessel CAD predicates against likely long-term success with PCI. Consequently, in the absence of contraindications to surgery, CABG should remain the standard of care for most patients with LMS stenosis because of its substantial survival advantage and freedom from repeat intervention. Percutaneous coronary intervention may be a reasonable alternative in those with isolated LMS stenosis not involving the bifurcation or those ineligible for CABG.<sup>11</sup>

Isolated ostial stenosis of the LMS coronary artery is rare, accounting for 1% of all coronary artery disease.<sup>1</sup> The cause is unclear, but may be arteriosclerosis, inflammatory processes affecting the surrounding aortic wall, or both. In at least 2 of our patients, aortic atherosclerosis and calcification was observed around the LMS coronary ostium. Traditionally, LMS coronary artery stenosis is treated by coronary artery bypass grafting. However, drawbacks include multiple vascular anastomoses (which consume bypass conduits and can lead to complications), permanent occlusion of the LMS coronary artery,<sup>1</sup> and less physiologic retrograde myocardial perfusion.<sup>12</sup>

## METHODOLOGY

This descriptive study was conducted from the properly maintained record of 3 years (January 2008 to December 2011) of cardiac catheterization lab of cardiology unit, a 1400 bedded, tertiary care hospital. Cardiology unit consists of 60 regular beds, well equipped cardiac care unit; highly organized cardiac catheterization lab with recent 6 cardiac catheterization machines and laboratory for all relevant investigation is available. The study was approved by the ethical review committee of the institution. All data was analysed using SPSS version 16.

## RESULTS

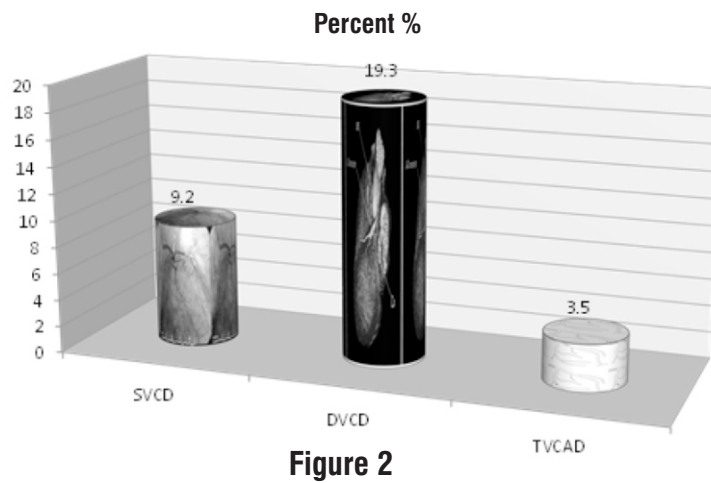
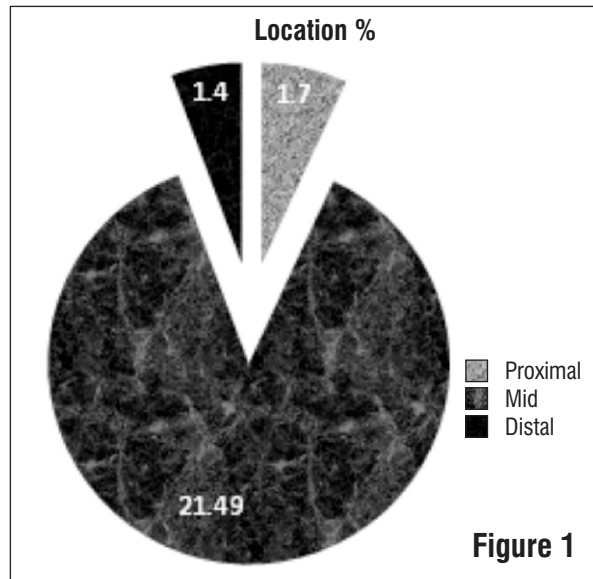
Total numbers of cases were 3950 in which Coronary angiographies were 2058. Among them patients having normal vessels were 497 (24.14%), single vessel disease (SVD) 389 (18.9%), double vessels disease (DVD) 350 (17%), triple vessels disease (TVD) 822 (39.94%) and patients having left main stem disease were (LMS) 228 (11.03%) Table 1. Mean age of patients having LMS disease was  $57.2 \pm 10.1$  years. 110 (48.2%) patients were above 60 years of age. Baseline characteristics of patients having LMS disease were given in Table 2. Mean LMS lesion was  $50.7 \pm 21$  of its diameter, in which more than 50% of the segment involved were 140 (61.41%). Locations of the lesion were 4 (1.7%) proximal, 49 (21.49%) mid and 175 (76.7%) distal LMS (Figure 1). Presentation of patients having LMS disease was stable angina in 136 (59.64%), acute myocardial infarction in 52 (22.8%) and acute coronary syndrome in 44

**Table 1: 3 Years Angiographic Reports**

Total angios	2058
Normal	497(24.14%)
Single vessel disease	389(18.9%)
Double vessel disease	350(17%)
Tripple vessel disease	822(39.94%)
Left main stem disease	228(11%)

**Table 2: Baseline Characteristics of Patients having LMS Disease**

Age(Mean)	57.2±10.1
Male	176 (77.2%)
Family History	79 (34.65%)
Diabetes Mellitus	151 (66.2%)
Hypertenson	172 (75.4%)
Hyperlipidemia	106 (46.49%)
Smoker	47 (20.61%)
Stable Angina	136 (59.64%)
Unstable Angina	44 (19.29%)
Acute Myocardial Infarction	52 (22.8%)



(19.29%). Numbers of coronary vessels involved were single vessels disease in 21 (9.2%), double vessels disease in 44 (19.3%) and triple vessels disease in 163 (71.5%) patients (Figure 2).

## DISCUSSION

Left main coronary artery (LMCA) disease remains an important risk factor for increased mortality and morbidity at all stages of diagnosis and treatment of coronary artery disease. Left main stem pathology is often silent, with unpredictable presentation: as such it poses diagnostic and management challenges. The LMCA runs from its origin in the aorta to its bifurcation into the left anterior descending and circumflex coronary arteries. The average diameter of a non-diseased LMCA measured angiographically is  $4.5 \pm 0.5$  mm in men, and  $3.9 \pm 0.4$  mm in women<sup>13</sup>, although diameters up to 10 mm have been recorded in post-mortem studies of non-diseased hearts. The length of the LMCA is highly variable: in one study of 106 hearts at autopsy the length ranged from 2 to 40 mm<sup>14</sup>.

Most trials of treatment and treatment guidelines define significant LMCA stenosis as a greater than 50% diameter stenosis, and left main equivalent disease is as severe (greater than or equal to 70%) diameter stenosis of the proximal left anterior descending and proximal left circumflex as judged by contrast angiography<sup>15</sup>. In our study the mean luminal diameter stenosis was the same as 50%. By far the most common aetiology of LMCA disease is atherosclerosis. The prevalence of significant LMCA atherosclerotic disease at angiography in men over 65 years of age presenting with New York Heart Association (NYHA) class II angina in one report was 11%, NYHA class III angina was 13% and NYHA class IV angina was 9%. These percentages were 0, 7 and 12, respectively, for females<sup>18</sup>. In our study the overall prevalence was 11% in all angiographic findings almost similar to other studies. In a study by Saeed Sadeghian et al showed that the proportion of the male sex in those with LMS was higher than that of the ones without LMS (87.8% vs. 71.4%,  $P=0.020$ ) and that patients with LMS were older (mean age of  $58.8 \pm 10.5$  years in those with LMS vs.  $55.6 \pm 9.2$  in the ones without LMS,  $P=0.03$ )<sup>17</sup>. In present study the mean age of presentation was  $57.2 \pm 10.1$ . and the proportion of male sex was 77.2%. It means that LMS disease is more common in male population and in advanced age group. In most studies Left main stem stenosis occurs as an isolated lesion in only 6% to 9% of patients, whereas over 70% to 80% of patients also have multivessel CAD<sup>4-10</sup>. Most LMS stenoses (40% to 94%) occur in the distal segment of the artery and extend into the proximal coronary arteries.<sup>4-10</sup>

In our study isolated LMS did not occur, and LMS was associated with SVD 21 (9.2%), DVD 44 (19.3%) and TVD 163 (71.5%). Regarding location of LMS stenosis Proximal 4 (1.7%), mid 49 (21.49%) and Distal 175 (76.7%). So our

results were similar to international studies regarding involvement of LMS with multivessel coronary artery disease and predominance of distal vessel involvement.

Left main stem disease can present in variety of ways depending upon the associated multivessel involvement. In our study the Clinical presentation of LMS were Stable angina = 136 (59.64%), ACS = 44 (19.29%), and AMI = 52 (22.8%). Intravascular ultrasound (IVUS) analyses have observed that plaque rupture rarely occurs in the LMS or the distal part of the coronary arteries, whereas it is far more common in the proximal part of the coronary vessels<sup>18</sup>, especially in the left anterior descending (LAD) artery<sup>19</sup>. The high prevalence of ACS and MI in our study could be due to high prevalence of multivessel involvement with LMS disease. Diabetes was also very common condition with LMS and multivessel disease in our study as cited by other studies.<sup>20</sup>

Coronary angiography remains the gold standard diagnostic modality in diagnosis of clinically important LMCA lesions. There are, however, several important limitations, which lead to a small but significant number of false-positive and false-negative results, as well as significant inter-observer variability<sup>21</sup>. In order to avoid precipitating myocardial ischaemia in patients with severe LMCA disease, operators try to limit the number of angiographic shots, as well as keep dye injections to a minimum: this may have an impact on diagnostic accuracy of less experienced operators. Ostial LMCA stenosis is not well shown angiographically, diagnosis relies on detection of pressure damping on engagement of the ostia with the catheter tip and the absence of reflux of dye into the coronary sinus on injection. Detecting and quantifying stenosis of the LMCA and bifurcation rely on a normal segment for comparison: the severity of concentric stenoses of the entire LMCA may therefore be underestimated. Several studies comparing conventional angiography with adjunctive imaging modalities have shown LMCA lesions considered angiographically indeterminate to, in fact, be severely stenosed.<sup>22</sup> Adjunctive technology, which is used to increase diagnostic accuracy and facilitate decision making, includes intravascular ultrasound imaging (IVUS), fractional flow reserve (FFR) and coronary vasodilatory reserve (CVR). Future studies are needed to show the effectiveness of these modalities in diagnosis of LMS disease.

## CONCLUSION

Left main stem disease is common angiographic finding and is associated with multivessel coronary artery disease and diabetes. It commonly occurs in distal part of vessel.

## REFERENCES

1. Ragosta M, Dee S, Sarembock IJ, Lipson LC, Gimble LW, Powers ER. Prevalence of unfavorable

- angiographic characteristics for percutaneous intervention in patients with unprotected left main coronary artery disease. *Catheter Cardiovasc Interv* 2006;68:357-62.
2. Keogh BE, Kinsman R. Fifth National Adult Cardiac Surgical Database Report 2003. UK: Dendrite Clinical Systems; 2004.
  3. De Lezo JS, Medina A, Pan M, Delgado A, Segura J, Pavlovic D, et al. Rapamycin-eluting stents for the treatment of unprotected left main coronary disease. *Am Heart J* 2004;148:481-5.
  4. Park SJ, Kim YH, Lee BK, Lee SW, Lee CW, Hong MK, et al. Sirolimus-eluting stent implantation for unprotected left main coronary artery stenosis: comparison with bare metal stent implantation. *J Am Coll Cardiol* 2005;45:351-6.
  5. Valgimigli M, van Mieghem CA, Ong AT, Aoki J, Granillo GA, McFadden EP, et al. Short- and long-term clinical outcome after drug-eluting stent implantation for the percutaneous treatment of left main coronary artery disease: (RESEARCH and T-SEARCH). *Circulation* 2005;111:1383-9.
  6. Price MJ, Cristea E, Sawhney N, Kao JA, Moses JW, Leon MB, et al. Serial angiographic follow-up of sirolimus-eluting stents for unprotected left main coronary artery revascularization. *J Am Coll Cardiol* 2006;47:871-7.
  7. Chieffo A, Morici N, Maisano F, Bonizzoni E, Cosgrave J, Montorfano M, et al. Percutaneous treatment with drug-eluting stent implantation versus bypass surgery for unprotected left main stenosis: a single-center experience. *Circulation* 2006;113:2542-7.
  8. Kim YH, Park SW, Hong MK, Park DW, Park KM, Lee BK, et al. Comparison of simple and complex stenting techniques in the treatment of unprotected left main coronary artery bifurcation stenosis. *Am J Cardiol* 2006;97:1597-601.
  9. Lee MS, Kapoor N, Jamal F, Czer L, Aragon J, Forrester J, et al. Comparison of coronary artery bypass surgery with percutaneous coronary intervention with drug-eluting stents for unprotected left main coronary artery disease. *J Am Coll Cardiol* 2006;47:864-70.
  10. Palmerini T, Marzocchi A, Marrozzini C, Ortolani P, Saia F, Savini C, et al. Comparison between coronary angioplasty and coronary bypass surgery for the treatment of unprotected left main coronary artery stenosis (the Bologna registry). *Am J Cardiol* 2006;98:54-9.
  11. Taggart DP, Kaul S, Boden WE, Ferguson TB Jr, Guyton RA, Mack MJ, et al. Revascularization for unprotected left main stem coronary artery stenosis: stenting or surgery. *J Am Coll Cardiol* 2008;51:885-92.
  12. Hitchcock JF, Robles de Medina EO, Jambroes G. Angioplasty of the main coronary artery for isolated left main coronary artery disease. *J Thorac Cardiovasc Surg* 1983;85:880-4.
  13. Dodge JT, Brown BG, Bolson EL, Dodge HT. Lumen diameter of normal human coronary arteries. Influence of age, sex, anatomic variation, and left ventricular hypertrophy or dilation. *Circulation* 1992;86:232-46.
  14. Bergelson BA, Tommaso CL. Left main coronary artery disease: assessment, diagnosis, and therapy. *Am Heart J* 1995;129:350-9.
  15. Smith SC, Feldman TE, Hirshfeld JW, Jacobs AK, Kern MJ, King SB, et al. ACC/AHA/SCAI 2005 guideline update for percutaneous coronary intervention: a report of the American College of Cardiology/American Heart Association Task Force on Practice Guidelines (ACC/AHA/SCAI Writing Committee to Update 2001 Guidelines for Percutaneous Coronary Intervention). *Circulation* 2006;113:e166-286.
  16. Fuster V, Alexander RW, O'Rourke RA, Roberts R, King SB, Nash IS, et al. 11th ed. *Hurst's the Heart*. USA: McGraw-Hill Professional; 2004.
  17. Sadeghian S, Karimi A, Salarifar M, Lotfi M, Tokaldany MD, Kazzazi EH, et al. Using workload to predict left main coronary artery stenosis in candidates for coronary angiography. *J Teh Univ Heart Ctr* 2007;3:145-50.
  18. von Birgelen C, Klinkhart W, Mintz GS, Papatheodorou A, Herrmann J, Baumgart D, et al. Plaque distribution and vascular remodeling of ruptured and nonruptured coronary plaques in the same vessel: an intravascular ultrasound study in vivo. *J Am Coll Cardiol* 2001;37:1864-70.
  19. Hong MK, Mintz GS, Lee CW, Lee BK, Yang TH, Kim YH, et al. The site of plaque rupture in native coronary arteries: a three-vessel intravascular ultrasound analysis. *J Am Coll Cardiol* 2005;46:261-5.
  20. Trianti M, Xanthos T, Iacovidou N, Dages N, Lekakis JP, Kyriakou F, et al. Relationship between individual cardiovascular risk factors and localization of coronary atherosclerotic lesions. *Heart Lung* 2011;40:201-7.
  21. Cameron A, Kemp HG, Fisher LD, Gosselin A, Judkins MP, Kennedy JW, et al. Left main coronary artery stenosis: angiographic determination. *Circulation* 1983;68:484-9.
  22. Mintz GS, Popma JJ, Pichard AD, Kent KM, Satler LF, Chuang YC, et al. Patterns of calcification in coronary artery disease. A statistical analysis of intravascular ultrasound and coronary angiography in 1155 lesions. *Circulation* 1995;91:1959-65.