

RIGHT ATRIAL MYXOMA

By

AZHAR M.A. FARUQUI, MBBS, FRCPC, FACC, SHAUKET ALI SYED, FCPS, FRCPE, FACC
and MOHAMMAD SHAREEF, FRCP(E).

INTRODUCTION

Among the primary tumors of the heart, myxomas are by far the commonest (1). The commonest site for myxomas is the left atrium (1). Right atrial myxomas are relatively rare with just over a dozen reported cases in the English language literature. We present here, we believe, the first case of right atrial myxoma to be reported from this sub-continent.

Case History:

A 45 years old lady started with symptoms of palpitations, atypical chest pains and dyspnea on exertion over a year prior to her referral to

this Institute. She was initially thought to be a cardiac neurotic until a physician heard a diastolic rumble and suspected mitral stenosis. A couple of months prior to her referral she developed transient amaurosis right eye which cleared up following anticoagulant therapy though a feeling of cloudy vision persisted. At the time of presentation, physical examination revealed a normotensive, slightly obese lady. Large visible and palpable 'a' waves were present in the jugular venous pulse. There was mild pedal edema and a mildly enlarged, non-tender liver. The precordium was quiet on palpation. S1 was loud with a normal S2. There was a grade III/VI diastolic rumble maximally audible along

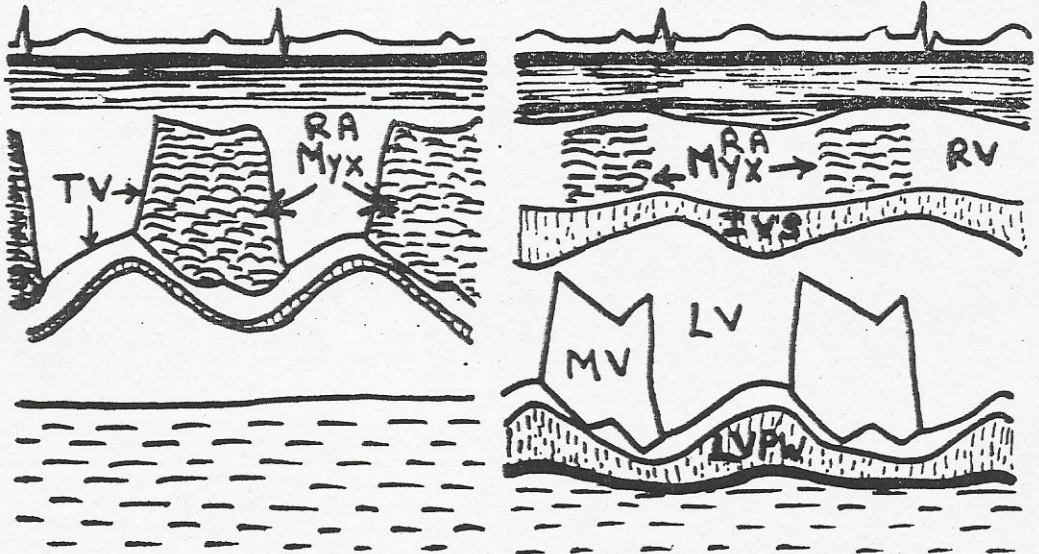


Fig. 1: Echocardiogram showing tumor echos behind the tricuspid leaflet and in the right ventricular cavity.

From the National Institute of Cardiovascular Diseases Rafiqui (H.J.) Shaheed Road, Karachi, Pakistan

the lower left sternal border. Carvalo's sign (increase in murmur with inspiration) was positive. Fundoscopy both eyes was normal and examination of other systems unrevealing. An ECG was unremarkable. Routine blood and urine examinations were normal. An X-Ray Chest showed moderate Cardiomegaly only.

An Echocardiogram was performed (Fig. 1) which elegantly showed a large right atrial tumor mass travelling back and forth across the tricuspid valve filling a considerable portion of the right atrium and entering the right ventricular inflow during diastole.

Cardiac Catheterization data is summarized in Table I. A right atrial angiogram was performed by injecting the dye bolus at the R.A.-S.V.C. junction without entering the body of the atrium. The angiogram (Fig. 2) showed a large egg shaped and egg sized mass rolling back and forth across the tricuspid valve exactly as in the Echogram. A left ventricular angiogram and coronary angiogram were normal. No neo-vascularization was apparent.

Patient underwent open heart surgery and excision of the myxoma abroad. At the time of surgery the right atrium and S.V.C. were greatly enlarged with thinning of the RA wall. On opening the R.A. the myxoma was found to be very large and friable and completely obstructing the tricuspid orifice. It was delivered with great difficulty after wide excision of the base. No A.S.D. or patent foramen ovale was noted. The post-operative course was complicated by chest infection, but otherwise uneventful. Pathologically, the tumor was found to be a benign myxoma.

On return to this Institute after surgery, the patient was re-examined and was found to

have a normal physical examination with no venous distension and normal cardiac auscultation. A repeat Echocardiogram (Fig. 3) showed absence of tumor echos behind the tricuspid valve. X-Ray chest showed a reduction in heart size. ECG showed non-specific T-wave changes (? pericarditis) only. Patient is fully mobile and, except for chest wall discomfort and effects of psychological stress and physical weakness, is normal.

DISCUSSION

Cardiac Myxomas have been thought to be a great masquerador of various diseases as the presentations may be varied and may cause the patient to end in different medical specialities.

The presenting features may include constitutional symptoms e.g. fever, immunologic abnormalities, embolic complications, congestive failure, pain, arrhythmias, syncope especially postural syncope or dizziness, asymptomatic murmurs, cardiomegaly and a history of surgery for a myxoma in the past (2).

Table I: Cardiac Catheterization Data

	Pressures	O ₂ Saturations
S.V.C.	a—15; v—7; mean—7 mmHg	66%
Aorta	110/60; mean—80 mmHg	99%
L.V.	110/0; EDP—5 mmHg	

R.A. Angiogram shows an egg shaped tumor occupying the body of the right atrium in systole and moving into the right ventricular inflow in diastole.

L.V. Angiogram shows a normal sized, non-thickened and normally functioning left ventricle.

Coronary Arteriogram shows a normal coronary arterial tree.

Right atrial myxoma like other chamber myxoma remains an enigma as far as its etiology is concerned. It may represent a true neoplasm either benign or malignant or it may represent myxomatous degeneration of a thrombus (3). Like the left atrial myxoma, the right atrial myxoma arises usually from the inter-atrial septum as it did in the case presented. While it is benign in the vast majority of cases, it may be malignant and even a pathologically benign looking myxoma may recur after a seemingly adequate resection (4).

The cause of generalized systemic immunologic problems seen with myxomas, like fever, raised sedimentation rate, myalgias and dysproteinemia is not well understood and may be absent as it was in our patient. The mechanical effects of the tumor are easy to understand and depend on the size and location of the tumor mass and the mobility that a long or short stalk allow it.

With right atrial myxoma it is common to see obstruction of the vena cavae either directly or a generalized rise in right atrial pressure by tricuspid valve blockade as in the case presented. Clinical findings would obviously depend on the type of blockade offered and in our case were exactly as in a case of tricuspid stenosis. The jugular venous congestion alongwith the large visible and palpable 'a' waves were what led to a careful auscultation and discovery of the characteristic auscultatory findings in this case. While a Carvalo's sign helps distinguish a right heart murmur from a left heart murmur, it is quite conceivable that such respiratory variation may be absent when venous obstruction is very severe and respiratory pressure variation rela-

tively small. As such, a high index of suspicion more than any thing else might lead to a pre-cath suspicion of this disease.

If a patent foreman ovale is present, it may be stretched open by an enlarged right atrium and allow right to left shunting with cyanosis and clubbing (5). A dangerous complication which may occur even in the absence of cyanosis is a paradoxical embolus to the arterial side.

It was our suspicion in this case that the transient amaurosis was an episode of paradoxical embolism, however, at surgery no A.S.D. or patent foramen ovale was found. As such no suitable explanation for the amaurosis can be forwarded except that the foramen ovale may have been patent the year and a half prior to surgery when the eye problem occurred or that the two conditions were unrelated.

Clinically, it may be impossible to distinguish tricuspid stenosis from a right atrial myxoma unless the myxoma is calcified when it may be seen flouoroscopically. Dynamic nuclear scanning or echocardiography can confirm the diagnosis pre-cath (6) as in this case. A right atrial angiogram is necessary to see the exact size of the tumor, its mobility and know if right to left shunting is occurring. Care has to be taken not to enter the body of the right atrium during catheterization as dislodgement of part of the myxoma or a clot on it may occur. While a left heart catheterization is not absolutely necessary, a coronary arteriogram may show the vascular supply of the myxoma (7). Such neo-vascularization was not seen in our case.

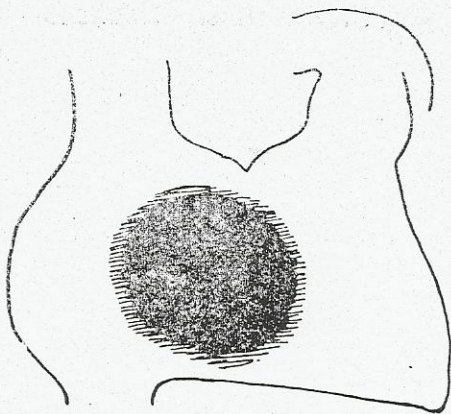


Fig. 2: Right atrial angiogram showing the myxoma crossing the tricuspid valve in diastole.

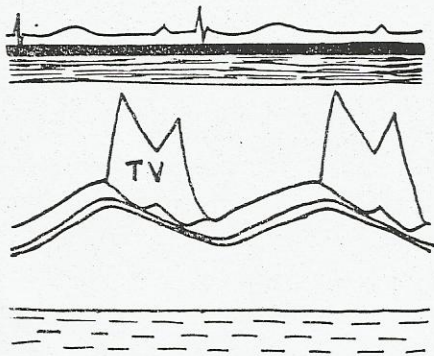


Fig. 3: Post-operative Echogram showing a normal tricuspid valve and no tumor echos.

Surgery for right atrial myxoma is simple though great care needs to be taken to prevent embolization and a wide resection of the base is essential to reduce chances of a recurrence. A concomitant Atrial septal defect may need to be closed and tricuspid valve repaired if damaged by the myxoma or even replaced if the tumor is attached to the tricuspid leaflet structure. Results are very gratifying, however, patient

needs to be under medical surveillance to detect early any recurrence of the myxoma in the same or another chamber (8).

ACKNOWLEDGEMENT

We are grateful to Surgeon A. Wychulis M.D. of New Jersey U.S.A. who sent a resume of the surgery he performed on this patient.

REFERENCES

1. Griffiths, G.C.: A Review of Primary Tumors of the Heart. *Prog. Cardiovasc. Dis.*, 7:465, 1975.
2. Greenwood, W.F.: Profile of Atrial Myxoma. *Am. J. Cardiol.*, 21:357, 1968.
3. Salyer W.R., Page D.L. and Hutchins G.M.: The Development of Cardiac Myxomas and Papillary Endocardial Lesions from Mural Thrombus, *Am. Heart J.*, 89:4, 1975.
4. Read R.C., White, H.J., Murphy M.L., et. al.: The Malignant Potentiality of Left Atrial Myxoma. *J. Thorac. Cardiovasc. Surg.*, 68:857, 1974.
5. Ralley R.C., Baldwin B.J., Symbas P.N. and Nutter D.O.: Right Atrial Myxoma. Unusual Presentation with Cyanosis and Clubbing, *Am. J. Med.*, 48:256, 1970.
6. Wolfe S.B., Popp R.L. and Feigenbaum H.: Diagnosis of Atrial Tumors By Ultrasound. *Circulation*, 39:615; 1969.
7. Berman N.D., McLaughlin R.P., Bigelow W.G. and Morch J.E.: Angiographic Demonstration of Blood Supply of Right Atrial Myxoma. *Br. Heart J.* 38:764, 1976.
8. Walton J.A., Khan D.R. and Willis P.W.: Recurrence of a Left Atrial Myxoma. *Am. J. Cardiol.*, 29:872, 1972.