

# Calcified Post Myocardial Infarction Left Ventricular

## Aneurysm in a Young Woman

*By*

Abdus Samad, M.D., Muhammad Rehman, F.R.C.S., A. Kundi, M.B.,B.S.,

A. Khakwani M.B.,B.S., and S.A. Syed, F.C.P.S., F.R.C.P., F.A.C.C.\*

Ten to twenty per cent cases of transmural myocardial infarction patients develop L.V. aneurysm but clinically it is recognised in a lesser number of patients. Transmural myocardial infarction in young menstruating females is rare. The majority of these are due to "Premature" atherosclerosis of the coronary arteries, but other causes like coronary embolism, coronary artery dissection, coronary arteritis and spasm are found in about 20% cases. Almost all of the atherosclerotic group have one or more major coronary risk factors (Diabetes, Hypertension, Hyperlipidemia, family history, contraceptive pills, smoking, Type-A personality, etc.). We describe here a case of a young fertile, menstruating, Pakistani woman having a calcified post myocardial infarction L.V. aneurysm due to obstruction of left anterior descending artery who had successful L.V. aneurysmectomy and Coronary bypass surgery. No major coronary risk factor could be discovered.

### Case History:

S.A. 35 years old Pakistani (born in India, immigrated to Pakistan in 1949 at the age of 3 years) woman was admitted to National Institute of Cardiovascular Diseases, Karachi, in February 1981 with severe retrosternal chest pain accompanied by profuse diaphoresis and vomiting. The E.C.G. showed evolution of an antero septal wall infarction. SGOT was 75, LDH was 96, Hb was 13.6 G%. The patient B.P., was 95/60 mm. Hg. on admission. She had an uneventful course in the hospital and was discharged after 12 days. She did not turn up for follow-up until May, 1981 when she was admitted again with history of recurrent retrosternal pain on exertion and two days history of Orthopnoea and nocturnal dyspnoea. Patient's E.C.G. was unchanged showing QS pattern in V2, V4 with persistent ST. elevations. Her enzymes (SGOT and LDH) remained normal. She was found to be in Severe

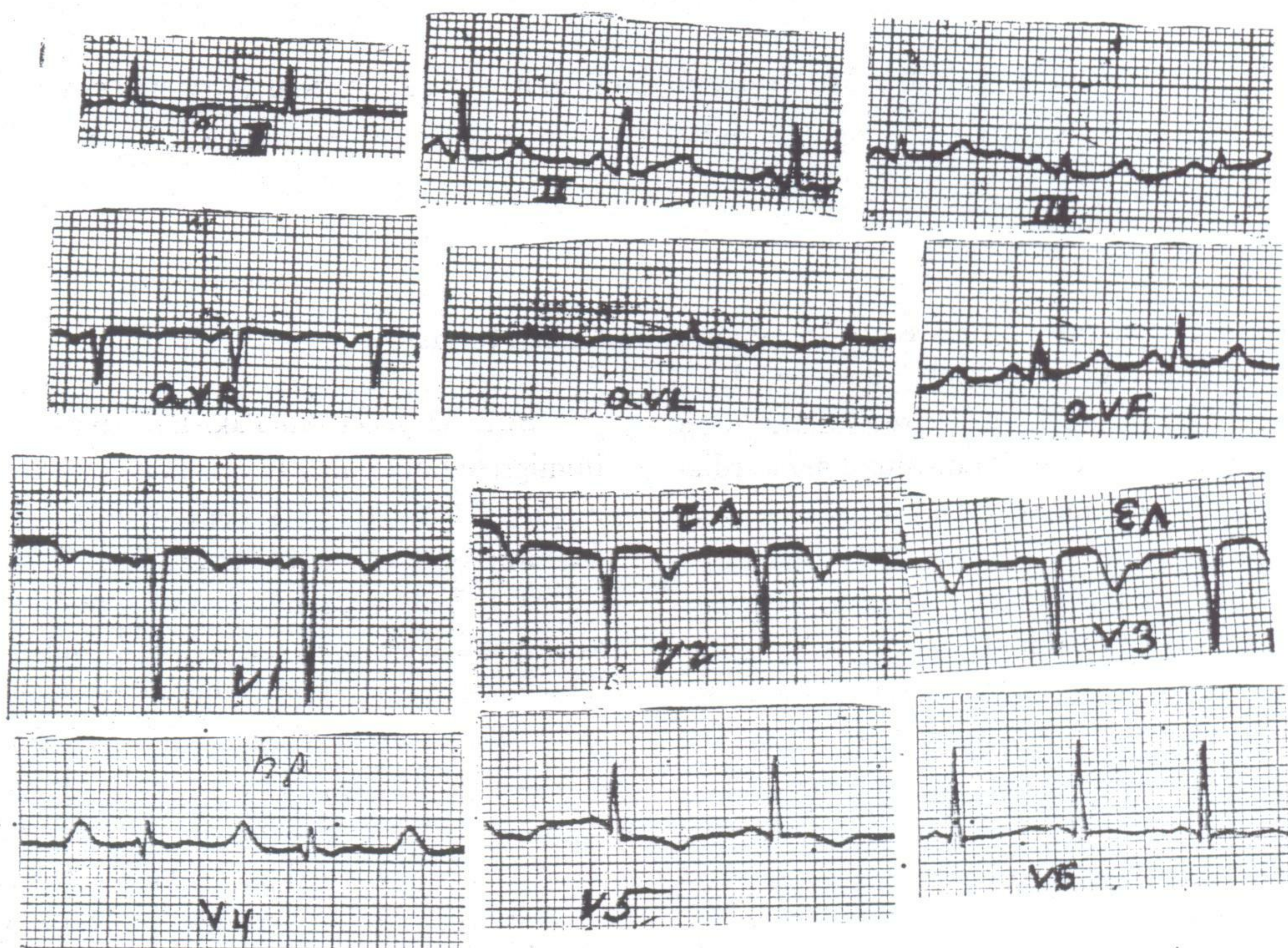
---

\*From the National Institute of Cardiovascular Diseases (Pakistan), Karachi.



LVF and was treated and responded well to large doses of I/V Lasix and Potassium Supplements. She was also digitalized slowly and Isordil 10 mg TDS was given. Patient was discharged on the 6th day.

She was admitted on 25th June, 1981 and had Coronary Angiography and left ventriculography on next day (See table I and Fig, 2, 3 & 4). Table II shows her blood sugar, serum Cholesterol, Other Lipids, Uric Acid and Blood Urea.



ECG of the patient soon after admission showing the changes of acute anteroseptal infarction.

The patient came to O.P.D. after 4 weeks and was found to be in mild LVF and continued to have angina of effort. She was advised admission which she refused. Fluoroscopy (Fig. 1) this time showed calcified Aneurysm of L.V.

The patient is married and has 3 children. The youngest one is 2-1/2 years old. She was not on any oral contraceptive therapy. There is no history of addiction to alcohol and tobacco. Mother is alive and healthy. Father died in accident.



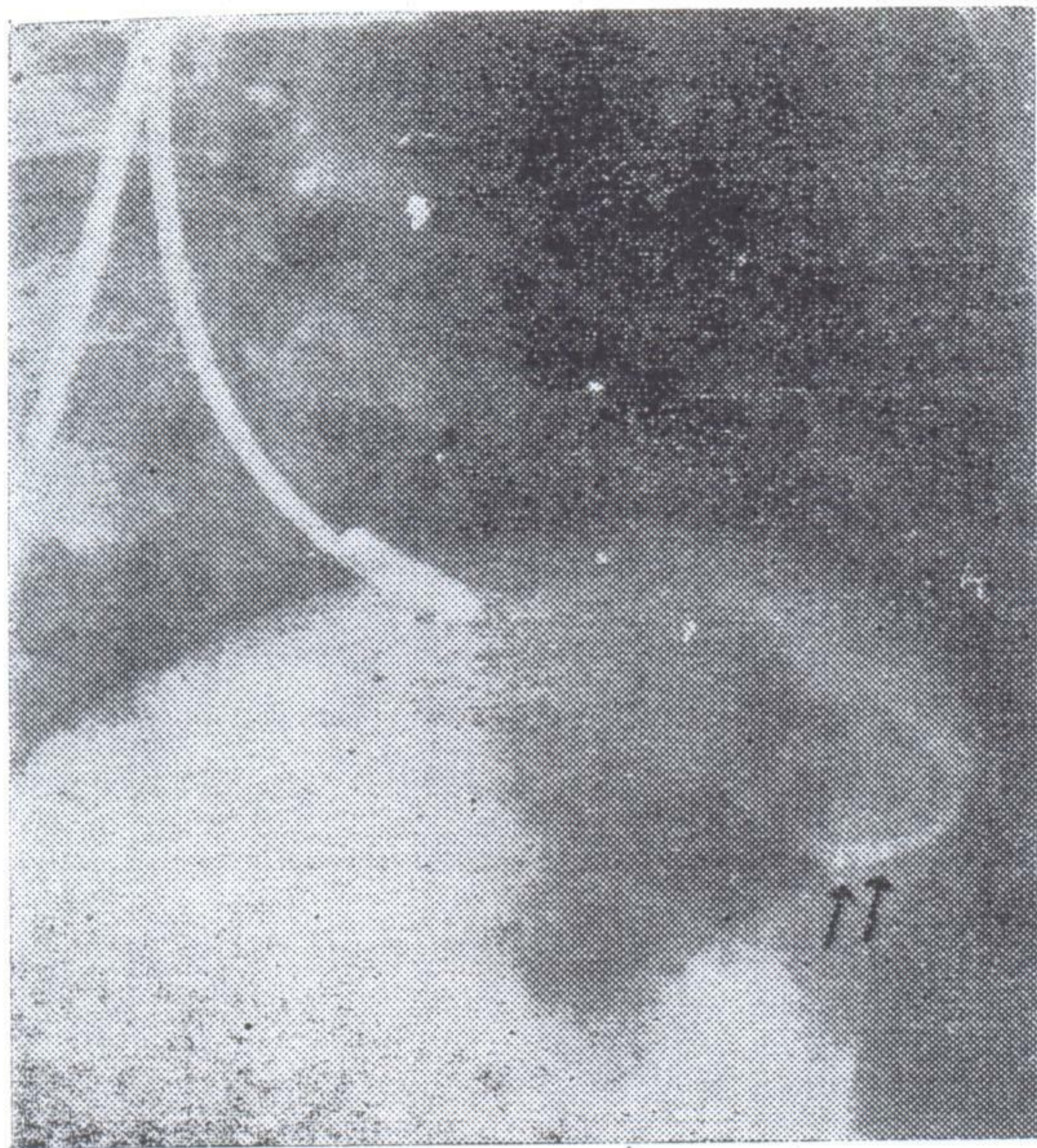


Fig. 1. Calcified wall of the L.V. aneurysm.

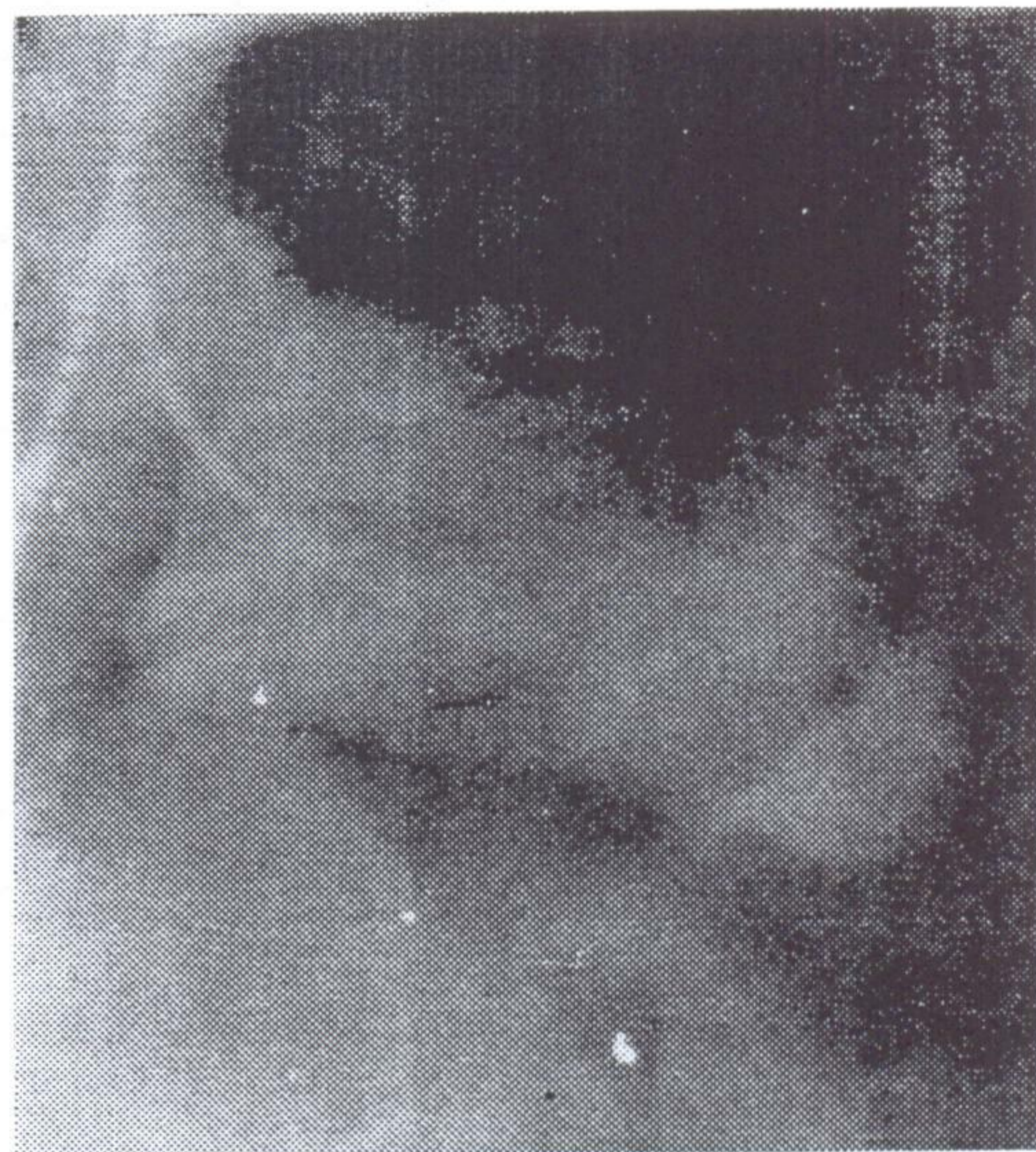


Fig. 2. End-systolic frame of L.V. angiogram.

**Table I: Left Ventriculogram and Coronary Angiogram Through (RT) Femoral Artery Percutaneous Approach**

L.V.: E.F.—50% L.V.E.D.P.—10 mm.Hg.  
Calcified aneurysm at the apex of L.V.,  
no clot seen. Anteroapical dyskinesia present.

L.C.A.: *Left main—Normal*

*L.A.D.*—Large branch coming around the  
apex, 95% stenosis in the proximal  
third.

*Circumflex*: Normal Main.

1st marginal 50% obstruction proximal  
region good distal vessel.

2nd marginal Normal

R.C.A.: Normal vessel, balanced.

*Diagnosis*: L.V. Calcified aneurysm

Two vessel C.A.D.

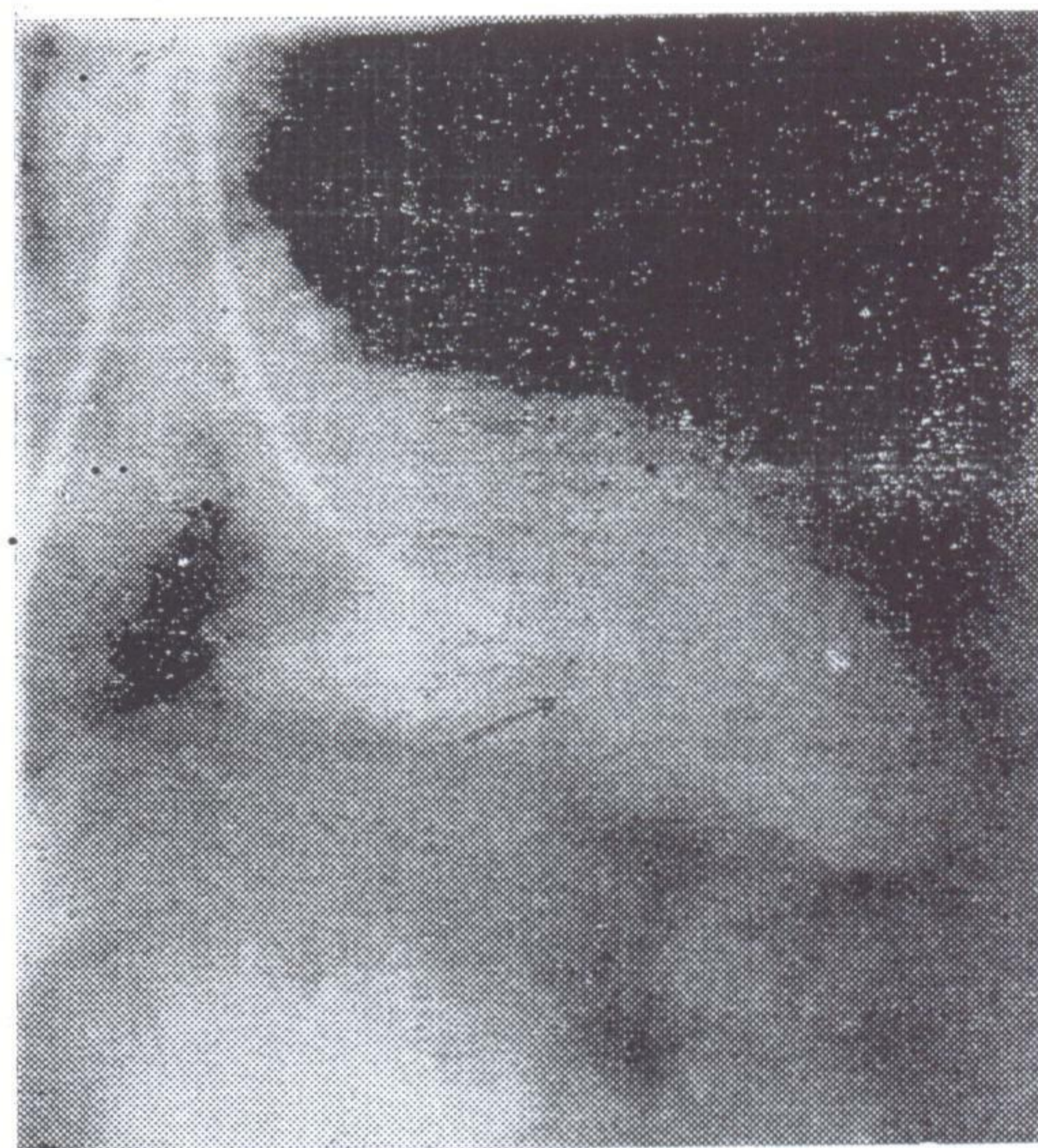

Fig. 3. End-diastolic frame of L.V. angiogram.



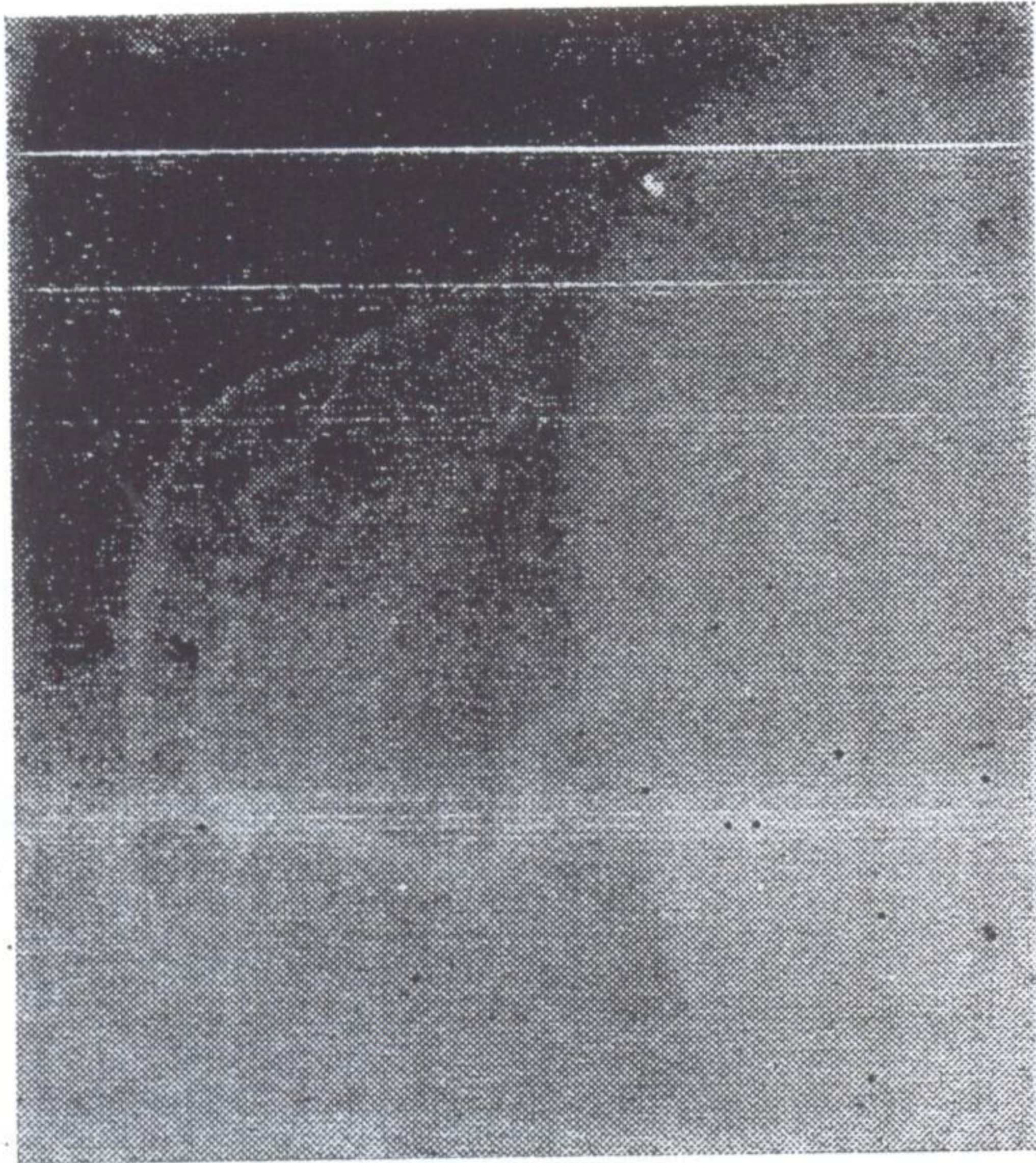


Fig. 4. Coronary Angiogram showing LAD and circ. lesions.

Table II: Biochemical Profile

|                     |         |
|---------------------|---------|
| F.B. Sugar          | 92 mg%  |
| Post prandial sugar | 105 mg% |
| Serum Cholesterol   | 189 mg% |
| Serum Triglycerides | 105 mg% |
| Serum Uric Acid     | 3.8 mg% |
| Blood Ured          | 28 mg%  |
| Ca                  | 9.5 mg% |
| K                   | 4.8 mg% |

Her menstrual cycle is regular 4-5/30 with moderate flow. Patient underwent left ventricular aneurysmectomy and L.A.D. Bypass with uneventful recovery.

## Discussion

It is well known that transmural myocardial infarction is quite uncommon in menstruating females<sup>1-2-3</sup>. The Framingham study<sup>4</sup> found clinically significant coronary artery disease in

only 1:1000 woman aged 30-39 years while myocardial infarction was found in only 0.19 per 1000 woman. In Sweden Bengtsson<sup>5</sup> in 1973 found annual incidence of Myocardial Infarction in Women age 35-38 years living in Goteberg Sweden to be 0.03 per 1000. A more recent study done in hospitalized patients by Morris et al<sup>6</sup> showed 24 instances of females below forty years having transmural myocardial infarction amongst 5158 patients diagnosed as Myocardial infarction over a period of seven years. Four of these patients had Coronary obstructions due to embolization, arteritis and dissecting aneurysm, one patient had patent coronary arteries and the rest had atherosclerotic narrowing and obstruction of the coronary arteries. Only 3 out of these 19 cases had anterior wall myocardial infarction. While Inferior wall infarction is more common in females with atherosclerotic coronary artery obstruction, anterior wall infarction caused by long, smooth, proximal segmental narrowing of the left anterior descending coronary artery is quite characteristic of oral contraceptive induced lesion<sup>7-8</sup>. It has been pointed out by various studies that atherosclerosis of the coronary arteries in young menstruating females is almost always associated with one or more major risk factors. Diabetes mellitus or hyperlipidaemia is present in over 95% cases<sup>9</sup>. Similarly Hypertension, Hyperlipidaemia, smoking and family history has been present in the rest of the cases. In the series of Morris<sup>7</sup> cases had history of oral contraceptive agents but all of them also had more than one additional risk factor present.

Ventricular aneurysm is defined as bulging of the myocardium due to excessive thinning. Angiographically the bulge of the ventricular silhouette should be present both in systole and diastole. If it is present in systole only then the



term dyskinesia is used and anatomic aneurysm may not be present.

In one autopsy study 12-20% cases of myocardial infarctions were found to have ventricular aneurysms<sup>10-11</sup>. The clinical recognition is much less. However single plane ventriculography detects most of the aneurysms. Calcification of the ventricular aneurysm is occasional<sup>12</sup>.

In addition to Myocardial Infarction ventricular aneurysm may be due to gumma, rheumatic carditis, trauma, Sarcoidosis and following surgical repair for Tetralogy<sup>12-14-15</sup>.

Our patient is interesting in the sense that no major risk factors could be discovered, either in the history in or the physical and biochemical examination. Secondly the aneurysm became calcified within 4 months of myocardial infarction. While there are reports of deposition of Calcium in fresh myocardial scars, but extensive myocardial calcification takes years. While rupture of calcified aneurysm is an extremely remote possibility myocardial aneurysm interferes with the function of the heart in three ways, viz:-

- (i) Lt. Ventricular failure resulting from (a) Loss of contraction of the aneurysmal portion of the myocardium (b) partial loss of systolic force of the remainder normal myocardium to expand the aneurysm rather than forward flow into the aorta. (c) If the papillary muscle is involved mitral regurgitation may result this is usually associated with inferoapical aneurysms.
- (ii) Production of Ventricular arrhythmias<sup>16-20</sup>.
- (iii) A mural thrombus may form in the aneurysm with subsequent embolisation.

Dubnow et al<sup>17</sup> found fifty two instances of mural thrombi in eighty cases of post infarction ventricular aneurysm. Thirty eight percent of these cases had systemic embolism.

The clinical course of patients with ventricular aneurysms varies, however more than 70% are dead within three years without resection.

In a study of twenty six patients by Jane Erik Otter Stad<sup>18</sup> undergoing L.V. aneurysmectomy thirteen had heart failure, 10 had angina and three had recurrent ventricular tachycardia. After a mean follow up of three and half years twenty one patients had improved, four unchanged and only one deteriorated. Repeat left ventricular angiography showed some residual aneurysm in 69% cases. They confirmed marked clinical and haemodynamic improvement after aneurysmectomy. They concluded that the major determinant of clinical and haemodynamic status is the amount of residual atherosclerosis in the remaining coronary vessels. Patients who have multiple vessels coronary artery disease tend to benefit less. Most studies have reported a reduction in the persistent elevation of ST segment after aneurysmectomy. The exact mechanism of this phenomenon is not known; but may be due to a reduction in the fibrotic area<sup>19</sup>.

In our patient the indication for aneurysmectomy included recurrent L.V.F. and severe angina pectoris. On operation a moderate sized aneurysm involving the apex and the anterior wall was found. Most of the aneurysm was calcified but no mural thrombus was present. The wall of aneurysm was extremely thin (1-2 mm). The L.A.D. was bypassed, diagonal branch of L.A.D. had diffuse disease. The right coronary artery and the circumflex system were free of any significant disease. The patient had uneventful recovery



and there is marked improvement in his clinical status.

The factors which lead to formation of Ventricular aneurysm after Myocardial Infarction are not clear. However, it has been pointed out that the process of infarction involves 3 stages.

1. Stage of necrosis.
2. Stage of expansion.
3. Stage of repair (Scar formation).

Aneurysm formation is associated with the last 2 stages. Thus any agent which leads to excessive thinning of the scar during the recovery stage results in aneurysm formation. Injections of methyl prednisolone during the acute phase of myocardial infarction leads to preservation and "mummified Cells" resulting in excessively thin scars and aneurysm formation in rats.

#### References

1. Underdahl L.O. et al: Coronary artery disease in women under the age of forty. Proc. Staff Meet Mayo Clinic, 22:479, 1947.
2. Weinred H.L., German E., Rosenberg B. A study of myocardial infarction in women. Ann Intern Med. 46:285, 1957.
3. Cochran R, Gwinup G: Coronary artery disease in young females. Arch Intern Med. 110:162, 1962.
4. Kagan A: Dawber TR et al: The Framingham study, Fed Proc, 21: Suppl 11:52, 1962.
5. Bengtsson C et al: Ischaemic Heart Disease in women. Acta Med Scand (Suppls) 49: 1-128, 1973.
6. Morris D. Hurst J.W. et al, Myocardial infarction in young women. Am. J. Cardiol 38:299-304, 1976.
7. Maleki M.I., Lange R.L. Coronary Thrombosis in young women on oral contraceptives. Am Heart J. 85:749-754, 1973.
8. Mann J.I. Inman W.H. Oral contraceptives and death from myocardial infarction. Br. Med. J., 2:445, 1976.
9. Abrams D.L. et al: Ventricular Aneurysm Circulation 27:164, 1963.
10. Schlichter, et al: Aneurysm of the heart Medicine (Balf) 33:43, 1954.
11. Salel A.F. et al: Predisposing factors in coronary heart disease. Am. J. Med. 57:987, 1974.
12. Fowler Noble O: Ventricular aneurysm In, Cardiac Diagnosis and Treatment. Second Edition (Noble Fowler et al) Hagerstown MD, Harper Row 1976, 693-694.
13. Killen D.A. Frana R: Post transitive Aneurysm of the L.V. Circulation 39:101, 1969.
14. Lull R.L. Dunn E.C. et al: Ventricular aneurysm due to cardiac sarcoidosis with surgical cure of refractory ventricular tachycardia Am. J. Cardiol 30:282, 1972.
15. Stansel H.C. Jr: R.V. aneurysm J. Thorac Cardiovasc Surg. 46:66, 1963.
16. Pujadas. Ventricular aneurysm: in coronary arteriography. Am. Ht. J. 70:753, 1965.
17. Dubenow, Burchell H.B. Titus J.L. Post infarction vent. aneurysm Am. Heart J. 70:753, 1965.
18. Otterstad J.E. et al: Long term results after L.V. aneurysmetomy. Br. Heart J. 45:427-33, 1981.
19. Gooch A.S. et al: Persistent S.T. elevation in L V. aneurysm before and after surgery. Am. Heart J. 98:4-11, 1979.
20. Klein G. Frank H. et al. Thorac Cardiovasc Surg. 26:423, 1980.