

Early Haemodynamic Changes After Pericardiectomy*

ARIF UR REHMAN

NADEEM AHMAD

MOHAMMAD REHMAN

Summary:

A study of 24 patients undergoing pericardiectomy at the NICVD Karachi is presented. An attempt was made to document haemodynamic responses at varying times after the pericardiectomy. Results show that no marked haemodynamics improvement, can be expected immediately after pericardiectomy. In addition, a thorough decortication over ventricles excising all the fibrous layers of pericardium is the most important step of pericardiectomy.

Constrictive pericarditis by definition is mechanical limitation of Cardiac filling (Paul AE, 1983)¹. Tuberculosis is the etiology in nearly all the cases seen locally. The disease though rare in the West, is still prevalent in our Country. Surgical excision of adherent fibrous pericardium is the only treatment and leads to permanent relief. It is generally believed that haemodynamic improvement starts immediately after the procedure is completed and takes the form of decrease in Central Venous Pressure and heart rate alongwith increase in blood pressure and urinary output.

The purpose of this study was to assess any haemodynamic improvement during and in early post-operative period.

Patients and Methods:

Twentyfour patients undergoing pericardiectomy were studied in this series. History and Physical examination alongwith preliminary investigations were recorded. 2-D Echocardiography and Cardiac Catheterization were performed to confirm the diagnosis, as well as to exclude any other associated pathology. All these patients were on anti-failure and anti-tuberculosis treatment pre-operatively.

General Anaesthesia was induced using pantothal alongwith pavulon and maintained by Oxygen-Nitrous Mixture with Halothane.

Surgery was performed through median sternotomy. Aorta and Pulmonary artery were decorticated, followed by right and then left ventricles. Lastly atria and then vena cavae were freed.

Parameters recorded during the procedure were heart rate, peripheral arterial pressure, right atrial pressure and high superior vena cavae pressure. All these pressures were recorded after the patients were anaesthetized, after the sternotomy, at various stages of decortication, at completion of pericardiectomy and six hours after surgery. During operation manipulation of heart was stopped for three minutes to stabilize the haemodynamic status of the patient before these parameters were recorded. All patients were put on Dobutamine support during the procedure to avoid any cardiac failure post-operatively. Inj. Lasix 80-100 mg intravenously was also given at the same time.

Results:

Pre-operatively all these patients had raised SVC and RA pressure (Table I). A drop in these pressures was recorded at two stages. First after the decortication of ventricles was completed and second; few minutes after the start of Iontropic support (Table I). Analysis of the change (Figure I) in pressure showed a significant drop due to Iontropic effect only. Analysis of high superior vena cava pressure (Figure II) showed no significant change in pressure before and after the completion of atrial and vena cava release.

* From the Department of Cardiac Surgery, National Institute of Cardiovascular Diseases, Karachi, Pakistan.

TABLE-I

	Heart rate beats/Minute ±SD	Mean Arterial Pressure (mm Hg.) ±SD	Right Atrial Pressure (mm Hg.) ±SD	Superior Vena Caval Pressure (mm Hg.) ±SD	Urinary output (ml/Hour) ±SD
*Before Sternotomy	87±18	72±18.3	28±9.2	28±10.1	35±12
After Sternotomy	94±16.8	91±16.1	28±18.6	28±18.6	8±3.8
Ventricular decortication	82±21.4	72±16.6	27±12.2	27±12.4	4±1.8
Dobutrex Infusion	91±17.8	89±12.3	25±14.8	25±14.8	4±2.3
Atria & Vena Caval Decortication	92±18.6	84±19.4	25±18.2	25±18.6	18±9.2
Sternal Closure	78±22.1	89±14	24±9.8	24±12.6	64±28.5
*6 Hours Post-op.	86±23	98±15.4	18±12.2	17±11.4	196±44.6

* Significant change.

FIGURE - I

Effect of Dobutamine on right atrial pressure

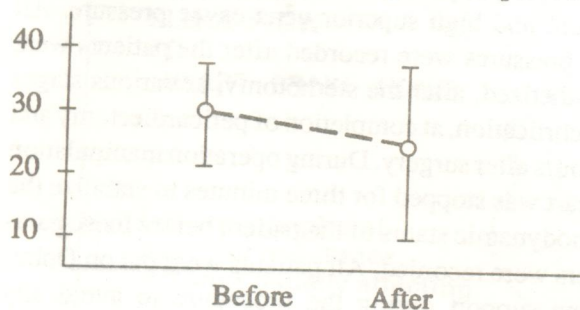
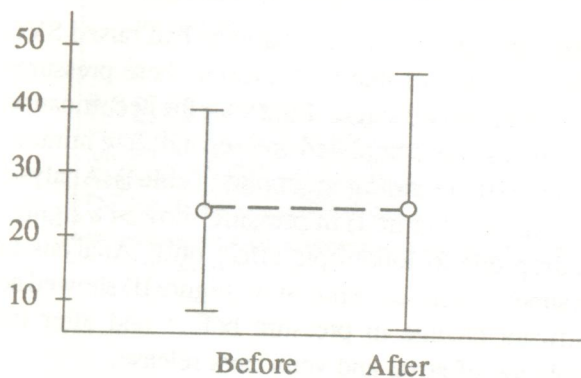


FIGURE - II

Effect of atrio-vena caval decortication on superior vena vaca pressure



A marked decrease in both right atrial and superior vena caval pressure and increases in arterial pressure was noticed in the last recording, taken six hours after the surgery.

Discussion:

Restricted Cardiac filling is the main factor responsible for congestive failure. Theoretically, it appears that after the excision of the constricting fibrous layer, a marked haemodynamic improvement will follow. This has led to the general belief that if the pericardiectomy is adequate, it will result in immediate drop in central venous pressure alongwith increase in blood pressure and urinary output (Shumacker HB & Rosh J. 1960)². Though all agree that this improvement continues for weeks till the atrophic myocardium gains its full strength (Wychullis AR et al. 1971)³.

All the patients in this study had adequate decortication. Still, no significant haemodynamic improvement was noted after the procedure. The only change of any significance was noted after the Dobutamine support was added. This showed that decortication itself was not the main cause for improvement in haemodynamic, but addition of Iontropics. This result can further be supported by the fact that in all the patients, right ventricle was relieved before its left counterpart. Pulmonary artery was already relieved. It could lead to Pulmonary congestion after the improve-

ment in stroke volume of right ventricle. Not a single patient had any pulmonary congestion during the procedure. Analysis of readings taken six hours after surgery showed an improved Cardiac output with resultant diuresis and drop in CVP. A closer look might suggest that through it did improve, but not to the extent as reflected by drop in central venous pressure and diuresis. Diuretics after completion of decortication might have contributed to the increased urinary output and thus drop in venous pressure.

Further, the only stage when central venous pressure dropped, was after the completion of ventricular decortication. No change was seen after decortication of atrial and venous cavo-pericardial attachment. For many years vena cavae constrictions have been blamed for failure of pericardiectomy (Parson HG & Holman E, 1955⁴, Culliford AT et al. 1980)⁵. Our study contradicts this view. How much the thin atrial walls fixed to fibrous pericardium have restricting role in the long run, needs further exploration.

Lastly, depressing effects of anaesthetics, minor surgical injuries and manipulation, on the myocardium might have added to low cardiac output in some of the cases during surgery.

References:

1. Paul AE. The Pericardium, In Gibbon's Surgery of the Chest, 4th ed. 1983.
2. Shumacker HB & Rosh J. Pericardiectomy, J Cardovinc Surg. 1,65, 1960.
3. Wychullis AR, Connolly DC, McGoon DC. Surgical treatment of Pericarditis, J. Thorac. Cardovinc Surg. 62, 608, 1971.
4. Parson HG and Holman E. Experimental Segmental Pericarditis. Arehn Surg. 70, 479, 1955.
5. Culliford AT, Lipton M, Spencer FC. Operation for Chronic Constrictive Pericarditis do the Surgical approach and degree of resection influence the outcome? Ann Thorac Surg. 29, 146, 1980.