

## ORIGINAL ARTICLE

## AN UPDATED META-ANALYSIS OF CLINICAL TRIALS AND OBSERVATIONAL STUDIES OF INTRAVASCULAR ULTRASOUND-VERSUS ANGIOGRAPHY-GUIDED LEFT MAIN STENTING

**Nimra Ashraf<sup>1</sup>, Muhammad Ahmed Ilyas<sup>1</sup>, Jaghat Ram<sup>1</sup>, Ejaz Ul Haq<sup>1</sup>, Zaryab Ahmed Khuwaja<sup>1</sup>, Gohar Riaz<sup>1</sup>, Ahmed Raheem<sup>2</sup>**

<sup>1</sup>National Institute of Cardiovascular Diseases (NICVD), Karachi, Pakistan, <sup>2</sup>Aga Khan University Hospital, Karachi, Pakistan

**Objectives:** This updated meta-analysis aimed to consolidate clinical evidence comparing the clinical outcomes of intravascular ultrasound (IVUS)-guided LMCA stenting versus conventional angiography-guided LMCA stenting.

**Methodology:** We included “randomized controlled trials” and “observational studies” published in peer-reviewed English language journals that compared the clinical outcomes of LMCA revascularization using “drug-eluting stents (DES)” via “IVUS-guided” versus “angiography-guided” stenting. The primary outcome of interest was “major adverse cardiovascular events (MACE)”, while secondary outcome variables included “all-cause mortality”, “myocardial infarction (MI)”, “target vessel/lesion revascularization (TVR/TLR)”, and “stent thrombosis (ST)”. Risk ratios (RRs) for each outcome variable were calculated using the “Mantel-Haenszel method”.

**Results:** The analysis included nine studies involving a total of 5,344 patients, with 2,282 undergoing “IVUS-guided” LMCA stenting and 3,062 undergoing “angiography-guided” LMCA stenting. “IVUS-guided” LMCA stenting showed a significant reduction in the risk of MACE compared to “angiography-guided” LMCA stenting, with a RR of 0.46 [95% CI: 0.27 - 0.79]. However, a high level of heterogeneity ( $I^2=94\%$ ;  $p<0.01$ ) was observed among the included studies. Additionally, “IVUS-guided” LMCA stenting was associated with significant reductions in all-cause mortality, MI, and ST, with RRs of 0.38 [0.21 - 0.66], 0.45 [0.26 - 0.77], and 0.24 [0.10 - 0.57], respectively. There was no statistically significant difference in TVR/TLR between “IVUS-guided” and “angiography-guided” LMCA stenting, with an RR of 0.64 [0.27 - 1.51].

**Conclusion:** “IVUS-guided” LMCA revascularization using DES was associated with a lower risk of MACE, death, MI, and ST compared to conventional “angiography-guided” LMCA stenting.

**Keywords:** meta-analysis, left main, intravascular ultrasound, angiography, drug-eluting stents, percutaneous coronary intervention

**Citation:** Ashraf N, Ilyas MA, Ram J, Haq EU, Khuwaja ZA, Riaz G, Raheem A. An Updated Meta-Analysis of Clinical Trials and Observational Studies of Intravascular Ultrasound- versus Angiography-guided Left Main Stenting. Pak Heart J. 2023;56(03):224-230. DOI: <https://doi.org/10.47144/phj.v56i3.2596>

### INTRODUCTION

Among the different types of obstructive “coronary artery disease (CAD)”, significant “left main coronary artery (LMCA)” disease stands out as the most high-risk subset of lesions, associated with poorer clinical outcomes as compared to the non-LMCA lesions.<sup>1</sup> For many years, “coronary artery bypass grafting (CABG)” has been the established standard of care for LMCA stenosis. However, due to notable advancements in device technology, the availability of improved antithrombotic therapy, and increased expertise of operators, “percutaneous coronary intervention (PCI)” has emerged as a viable alternative

technique for a significant number of patients.<sup>1-4</sup> Randomized clinical trials (RCTs) comparing PCI with “drug-eluting stents (DES)” and CABG have influenced the “2017 US appropriate use criteria” and “2018 European Guidelines”, which recommend PCI as an appropriate alternative to CABG for patients with low-to-intermediate anatomical complexity LMCA diseases.<sup>5-6</sup>

Despite the rapid expansion of LMCA PCI in real-world clinical practice supported by compelling evidence, intervention for this high-risk anatomical lesion remains challenging, with several unresolved technical challenges to overcome.<sup>7</sup> Precise pre-PCI

anatomical assessment, including lesion morphology, vessel size and diameter, and carina delineation, as well as post-PCI evaluation encompassing adequate stent expansion and apposition, assessment of side branches and carina, and identification of edge dissections, are crucial to ensuring the long-term durability and optimizing procedural outcomes of LMCA PCI. Consequently, there has been an increased utilization of intracoronary imaging as an adjunctive tool during PCI.<sup>7,8</sup> Unlike angiography, which underestimates lesion length, vessel size, and the degree of calcification, intravascular imaging, such as “intravascular ultrasound (IVUS)” and “optical coherence tomography (OCT)”, provides more detailed information about the vascular lumen and wall, thus guiding the intervention therapy.<sup>9,10</sup> As a result, intravascular imaging is becoming more widely used in PCI compared to angiography.<sup>10</sup>

However, LMCA lesions were either excluded or underrepresented in most of the aforementioned trials. Nevertheless, a meta-analysis of a limited number of clinical trials and observational data has demonstrated better clinical outcomes for “IVUS-guided” LMCA stenting compared to conventional “angiography-guided” LMCA stenting.<sup>11-14</sup> With the emergence of newer clinical evidence regarding the effect of “IVUS-guided” LMCA stenting, it is essential to synthesize the available clinical evidence to assist clinicians in making better-informed clinical decisions. Thus, the aim of this updated meta-analysis was to consolidate the clinical evidence, including trials and observational studies, regarding the effect of “IVUS-guided” LMCA stenting versus conventional “angiography-guided” LMCA stenting on clinical outcomes.

## METHODOLOGY

The PRISMA (“Preferred Reporting Items for Systematic Reviews and Meta-Analyses”) guidelines are adopted for the reporting of this meta-analysis.<sup>15</sup>

**Sources:** The literature search was performed by two independent investigators. The search engines, electronic libraries, and databases included Google Scholar, Web of Science, PubMed/MEDLINE, Cochrane Library, and EMBASE.

**Search Strategy:** The search string consisted of mesh and a combination of pre-specified terms that included; “left main,” “left main coronary artery,” “LMCA,” “left main coronary disease,” “left main lesion,” “left main coronary stenosis,” “stenting,” “stent placement,” “stent deployment,” “percutaneous coronary intervention,” “PCI,” “angiography,” “angiography-guided,” “ultrasonography,”

“intravascular ultrasound,” “intravascular ultrasound-guided,” “IVUS,” and “IVUS-guided”. The computerized search was limited to the publication year from January 2000 to May 2023. Further, references list of earlier meta-analyses regarding IVUS- versus “angiography-guided” PCI were also relieved for the potential data specific to the LMCA stenting.

**Study Selection Criteria:** We included both “randomized controlled trials” and “observational studies”, with or without adjustment, original articles published in peer-reviewed English language journals met the inclusion criteria of LMCA stenting via “IVUS-guided” PCI versus “angiography-guided” PCI and reported the clinical outcome of at least 12-month follow-up. Studies with either bare-metal stent or a mix of bare-metal stent and drug-eluting stent (DES) without separate reporting for DES were excluded. Studies without the head-to-head comparison of “IVUS-guided” and “angiography-guided” LMCA stenting, case reports/series, or meta-analysis were also excluded. Conference papers/abstracts or manuscripts with inaccessible full text or reporting deficiencies limiting the extractability of data regarding target clinical outcomes were excluded.

**The outcome of interest:** The primary outcome of interest was; “major adverse cardiovascular events (MACE)” and the secondary outcome variables included; “all-cause mortality,” “myocardial infarction (MI),” “target vessel/lesion revascularization (TVR/TLR),” and “stent thrombosis (either definite or probable)”.

**Assessment of Quality:** Selected studies and trials were assessed for methodological quality by two independent investigators. The observational studies were assigned a quality score ranging from 0 to 9 using the Newcastle-Ottawa scale (NOS), with higher ratings indicating better quality and a score of  $\geq 6$  considered as good quality.<sup>16</sup> The methodological quality of clinical trials was assessed using Jadad scoring, ranging from 0 to 5, with a score of  $\geq 3$  considered as good quality.<sup>17</sup>

**Statistical Analysis:** The Mantel-Haenszel method was used to compute the relative risk (RR) and “corresponding 95% confidence interval (CI)” to compare “IVUS-guided” LMCA stenting versus conventional “angiography-guided” LMCA stenting for the risk of “MACE,” “all-cause mortality,” “myocardial infarction,” “target vessel/lesion revascularization,” and “stent thrombosis”. Heterogeneity among the studies was assessed with the help of Higgins' and Thompson's  $I^2$  statistics and

Cochran's Q statistic. With the evidence of heterogeneity, the random effect model was applied. The meta-analysis was performed with the help of an open source software, R version 4.3.1, and packages "meta" and "metasens" were used.

## RESULTS

Search queries on electronic databases with predefined search strings returned a total of 1487 results, out of which 631 were duplicate results; hence, a total of 856 cases were screened for relevance based on inclusion criteria, and finally, nine articles were included for quantitative synthesis and meta-analysis. A flowchart was created to illustrate the study selection process, including the number of records identified, records screened, full-text articles assessed for eligibility, and final studies included in the analysis (Figure 1).

Among the selected articles, two were randomized clinical trials,<sup>18,19</sup> while the remaining seven studies were observational studies with or without adjustment.<sup>7, 20-25</sup> The study population for most of the articles was patients with unprotected LMCA diseases revascularized with DES,<sup>7,16-23,25</sup> except for one study that included non-complex LMCA diseases treated with a single stent technique.<sup>24</sup>

The nine included studies comprise 5344 patients, with 2282 with "IVUS-guided" LMCA stenting and 3062 with "angiography-guided" LMCA stenting. The follow-up duration of the nine studies ranges from 1 year to 10 years. The quantitative synthesis of clinical characteristics for the included studies is summarized in Table 1.

The "IVUS-guided" LMCA stenting significantly reduces the risk of MACE as compared to "angiography-guided" LMCA stenting with a risk

ratio (RR) of 0.46 [95% CI: 0.27 – 0.79]. However, a high heterogeneity ( $I^2=94\%$ ;  $p<0.01$ ) was observed among the included studies, as presented in Figure 2.

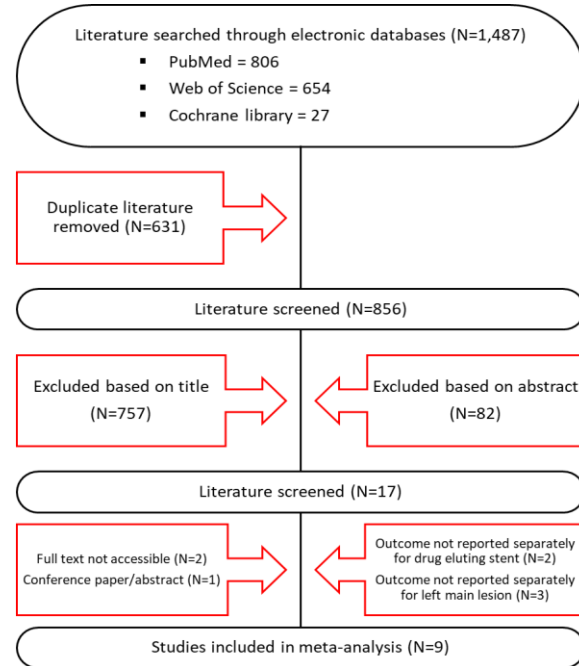


Figure 1: Study selection flow chart

Similarly, "IVUS-guided" LMCA stenting was observed to be associated with a significant reduction in all-cause mortality, MI, and stent thrombosis with RR of 0.38 [0.21 - 0.66], 0.45 [0.26 – 0.77], and 0.24 [0.10 – 0.57], respectively. TVR/TLR was not statistically significant between IVUS- and angiography-guided LMCA stenting with an RR of 0.64 [0.27 – 1.51] (Figure 3)

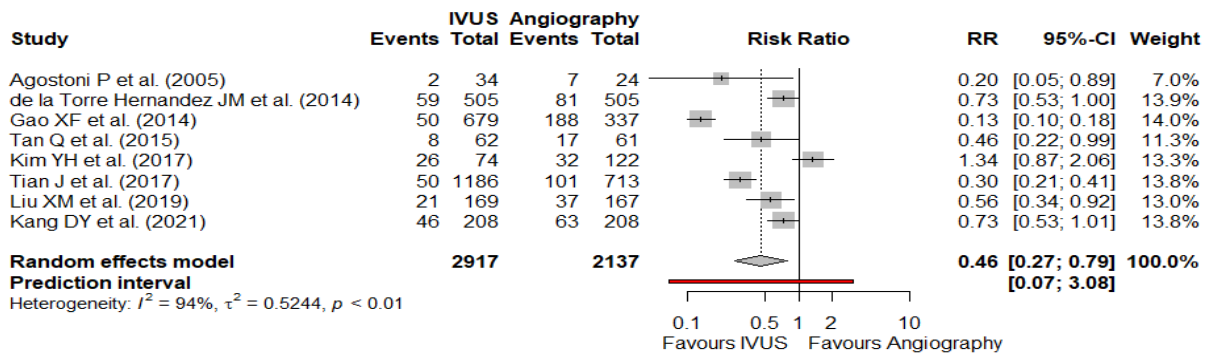
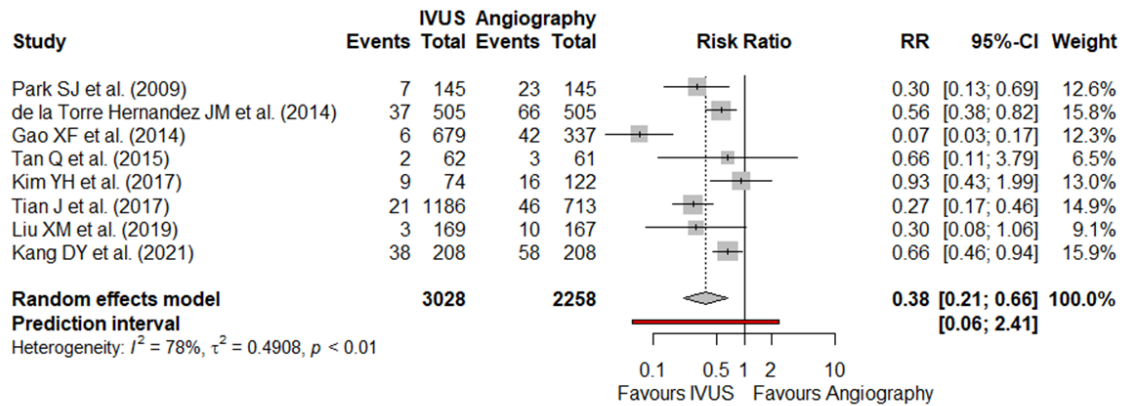


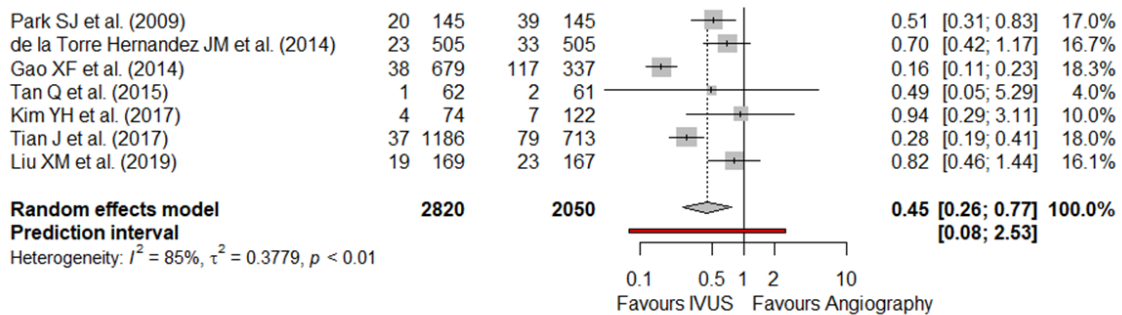
Figure 2: Forest plot for major adverse cardiovascular events

IVUS=" intravascular ultrasound", RR="risk ratio", CI="confidence interval"

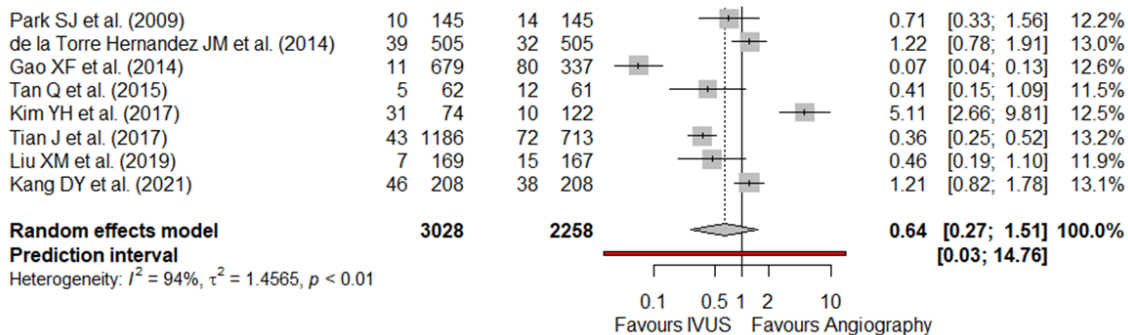
**A – All cause mortality**



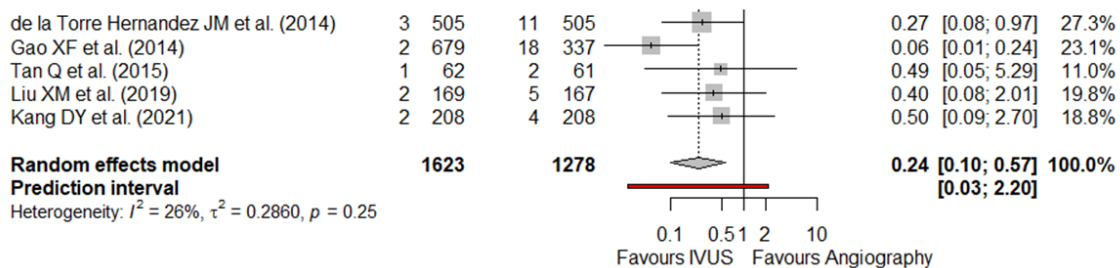
**B – Myocardial infarction**



**C – Target vessel/lesion revascularization**



**D – Stent thrombosis**



**Figure 3: Forest plot for all-cause mortality (A), myocardial infarction (B), target vessel/lesion revascularization (C), and stent thrombosis (D)**

IVUS= "intravascular ultrasound", RR="risk ratio", CI="confidence interval"

**Table 1: Distribution of patients’ medical history and clinical characteristics among included trial**

| Study                                  | Study Design | Quality | Follow-up (months) | Total Patients |      | Male    |      | Age (mean years) |      | HTN     |      | Diabetes |      | Smoking |      |
|--|--------------|---------|--------------------|----------------|------|---------|------|------------------|------|---------|------|----------|------|---------|------|
|  |              |         |                    | Control        | IVUS | Control | IVUS | Control          | IVUS | Control | IVUS | Control  | IVUS | Control | IVUS |
| Agostoni P et al. (2005)               | OBS          | 7       | 14                 | 34             | 24   | 25      | 15   | 64               | 62   | 20      | 14   | 10       | 9    | 7       | 4    |
| Park SJ et al. (2009)                  | OBS          | 9       | 36                 | 145            | 145  | 102     | 102  | 65               | 64.2 | 85      | 86   | 49       | 49   | 30      | 28   |
| de la Torre Hernandez JM et al. (2014) | OBS          | 9       | 36                 | 505            | 505  | 397     | 404  | 66.9             | 66.1 | 325     | 342  | 175      | 183  | 161     | 148  |
| Gao XF et al. (2014)                   | OBS          | 9       | 12                 | 679            | 337  | 526     | 274  | 67.1             | 66   | 489     | 244  | 232      | 109  | 230     | 111  |
| Tan Q et al. (2015)                    | RCT          | 4*      | 24                 | 62             | 61   | 43      | 38   | 75.8             | 76.5 | 29      | 25   | 18       | 21   | 29      | 27   |
| Kim YH et al. (2017)                   | OBS          | 6       | 36                 | 74             | 122  | 53      | 95   | 65               | 62   | 54      | 75   | 33       | 47   | 37      | 60   |
| Tian J et al. (2017)                   | OBS          | 8       | 36                 | 1186           | 713  | 920     | 576  | 60               | 60   | 654     | 400  | 314      | 173  | 316     | 256  |
| Liu XM et al. (2019)                   | RCT          | 5*      | 12                 | 169            | 167  | 108     | 106  | 64.9             | 65.3 | 122     | 116  | 52       | 56   | 60      | 62   |
| Kang DY et al. (2021)                  | OBS          | 9       | 120                | 208            | 208  | 152     | 156  | 64.5             | 64.6 | 109     | 107  | 69       | 70   | 48      | 54   |

IVUS= "intravascular ultrasound", RCT="randomized controlled trial"

\*Study methodological quality assessed using Jadad scoring

**DISCUSSION**

Percutaneous revascularization with drug-eluting stents (DES) is an emerging approach for LMCA patients, thanks to advancements in techniques and devices. However, despite these advancements in real-world clinical practice, intervention for this high-risk anatomical lesion remains challenging, and unresolved technical issues persist. Several studies have presented compelling evidence supporting the use of intravascular ultrasound (IVUS)-guided stent placement for LMCA patients.<sup>7, 16-23, 25</sup> Therefore, our updated meta-analysis, comprising nine studies, consolidated the clinical evidence by comparing the outcomes of “IVUS-guided” LMCA stenting versus conventional “angiography-guided” LMCA stenting.

In the analysis involving 5,344 LMCA patients with 2,282 undergoing “IVUS-guided” PCI, “IVUS-guided” PCI demonstrated a 54% reduction in major adverse cardiovascular events (MACE), a 62% decrease in the all-cause death rate, a 55% lower risk of MI, and a 76% decrease in stent thrombosis compared to conventional “angiography-guided” PCI. However, no statistically significant difference was observed in target vessel/lesion revascularization (TVR/TLR) between the two approaches. It is important to note that we observed high heterogeneity among the studies, particularly in one study involving

patients with non-complex LMCA diseases, which showed no significant differences between the two approaches.<sup>24</sup>

Angiography is considered the gold standard modality for assessing atherosclerosis in coronary arteries. However, it has limitations due to its 2-dimensional projection compared to the 3-dimensional projection provided by intravascular ultrasound (IVUS).<sup>26</sup> Secondly, the judgmental angiographic assessment of disease severity has higher intra- and inter-observer variability.<sup>12</sup> IVUS offers more detail and granularity, allowing interventionists to obtain more comprehensive information about lesion characteristics and morphology. This enhanced visualization enables them to make more informed decisions regarding optimal stent implantation. By providing a detailed and comprehensive view of the vessel, IVUS assists in achieving better precision during the intervention procedure.<sup>26</sup> In addition to unprotected left main disease, IVUS-guided stent placement has been found to be associated with better clinical outcomes for patients with complex coronary lesions such as chronic total occlusions, long lesions, bifurcations, and severe calcification.<sup>27,28</sup>

The available data regarding the clinical benefits of “IVUS-guided” stent placement, specifically in patients with LMCA disease, is quite limited, especially from randomized controlled trials (RCTs).

To the best of our knowledge, only two RCTs were conducted in single-center settings,<sup>18,19</sup> and both studies had relatively small sample sizes. Most of the evidence in this area comes from observational studies that have not been adjusted for potential confounding factors. Therefore, it is important to acknowledge that the findings may be influenced by differences in the clinical characteristics of the two groups being compared. Given the scarcity of RCT data and the potential limitations of observational studies, further research with larger sample sizes and controlled settings is needed to provide more robust evidence on the clinical benefits of “IVUS-guided” stent placement in LMCA patients.

Several limitations of the present meta-analysis need to be acknowledged. Firstly, it is essential to note that this analysis was conducted at the study level rather than the patient level. This distinction may limit the assessment of various confounding factors that could influence the outcomes. Secondly, out of the nine included studies, seven were observational, which introduced variability in the study population. Additionally, MACE's definition and categorization criteria may have needed to be more consistent across the studies. Moreover, the varying lengths of follow-up in the included studies can also be considered a limitation of this analysis. These limitations should be considered when interpreting the results and considering the implications of the findings.

## CONCLUSION

Based on the findings of this updated meta-analysis, it can be concluded that the use of “IVUS-guided” implantation of DES for LMCA patients shows potential clinical value by reducing the risk of MACE, all-cause mortality, MI, and ST compared to conventional “angiography-guided” LMCA stenting. However, it is important to note that there is high heterogeneity among the studies included in this analysis. Therefore, multicenter and large-scale clinical trials are necessary to confirm the clinical superiority of “IVUS-guided” PCI for LMCA patients.

## AUTHORS' CONTRIBUTION

NA, MAI, JR and EUH: Concept and design, data acquisition, interpretation, drafting, final approval, and agree to be accountable for all aspects of the work. ZAK, GR, and AR: Data acquisition, interpretation, drafting, final approval and agree to be accountable for all aspects of the work.

**Conflict of interest:** Authors declared no conflict of interest.

## REFERENCES

1. Lee PH, Ahn JM, Chang M, Baek S, Yoon SH, Kang SJ, et al. Left main coronary artery disease: secular trends in patient characteristics, treatments, and outcomes. *J Am Coll Cardiol.* 2016;68(11):1233-46.
2. Giacoppo D, Colleran R, Cassese S, Frangieh AH, Wiebe J, Joner M, et al. Percutaneous coronary intervention vs coronary artery bypass grafting in patients with left main coronary artery stenosis: a systematic review and meta-analysis. *JAMA cardiol.* 2017;2(10):1079-88.
3. Park DW, Ahn JM, Park SJ, Taggart DP. Percutaneous coronary intervention in left main disease: SYNTAX, PRECOMBAT, EXCEL and NOBLE—combined cardiology and cardiac surgery perspective. *Ann Cardiothorac Surg.* 2018;7(4):521-6.
4. Ahmad Y, Howard JP, Arnold AD, Cook CM, Prasad M, Ali ZA, et al. Mortality after drug-eluting stents vs. coronary artery bypass grafting for left main coronary artery disease: a meta-analysis of randomized controlled trials. *Eur Heart J.* 2020;41(34):3228-35.
5. Neumann FJ, Sousa-Uva M, Ahlsson A, Alfonso F, Banning AP, Benedetto U, et al. 2018 ESC/EACTS Guidelines on myocardial revascularization. *Eur Heart J.* 2019;40(2):87-165.
6. Patel MR, Calhoun JH, Dehmer GJ, Grantham JA, Maddox TM, Maron DJ, et al. ACC/AATS/AHA/ASE/ASNC/SCAI/SCCT/STS 2016 Appropriate Use Criteria for Coronary Revascularization in Patients With Acute Coronary Syndromes: A Report of the American College of Cardiology Appropriate Use Criteria Task Force, American Association for Thoracic Surgery, American Heart Association, American Society of Echocardiography, American Society of Nuclear Cardiology, Society for Cardiovascular Angiography and Interventions, Society of Cardiovascular Computed Tomography, and the Society of Thoracic Surgeons. *J Am Coll Cardiol.* 2017;69(5):570-91.
7. Kang DY, Ahn JM, Yun SC, Park H, Cho SC, Kim TO, et al. Long-term clinical impact of intravascular ultrasound guidance in stenting for left main coronary artery disease. *Circ Cardiovasc Interv.* 2021;14(10):e011011.
8. Koskinas KC, Nakamura M, Räber L, Colleran R, Kadota K, Capodanno D, et al. Current Use of Intracoronary Imaging in Interventional Practice—Results of a European Association of Percutaneous Cardiovascular Interventions (EAPCI) and Japanese Association of Cardiovascular Interventions and Therapeutics (CVIT) Clinical Practice Survey. *Circ J.* 2018;82(5):1360-8.
9. Shammam NW, Radaideh Q, Shammam WJ, Daher GE, Rachwan RJ, Radaideh Y. The role of precise imaging with intravascular ultrasound in coronary and peripheral interventions. *Vasc Health Risk Manag.* 2019;15:283-90.
10. Hoang V, Grounds J, Pham D, Virani S, Hamzeh I, Qureshi AM, et al. The role of intracoronary plaque imaging with intravascular ultrasound, optical coherence tomography, and near-infrared spectroscopy in patients with coronary artery disease. *Curr Atheroscler Rep.* 2016;18(9):57.
11. Elgendy IY, Gad M, Mintz GS. Meta-Analysis of intravascular ultrasound-guided drug-eluting stent implantation for left main coronary disease. *Am J Cardiol.* 2020;128:92-3.
12. Ye Y, Yang M, Zhang S, Zeng Y. Percutaneous coronary intervention in left main coronary artery disease with or without intravascular ultrasound: a meta-analysis. *PLoS One.* 2017;12(6):e0179756.
13. Elgendy IY, Gad M, Jain A, Mahmoud AN, Mintz GS. Outcomes with intravascular ultrasound-guided drug eluting stent implantation for unprotected left main coronary lesions: a meta-analysis. *Am J Cardiol.* 2019;124(10):1652-3.
14. Wang Y, Mintz GS, Gu Z, Qi Y, Wang Y, Liu M, et al. Meta-analysis and systematic review of intravascular ultrasound versus angiography-guided drug eluting stent implantation in left main coronary disease in 4592 patients. *BMC Cardiovasc Disor.* 2018;18:115.

15. Moher D, Liberati A, Tetzlaff J, Altman DG; PRISMA Group. Preferred reporting items for systematic reviews and meta-analyses: the PRISMA statement. *PLoS Med.* 2009;6(7):e1000097.
16. Peterson J, Welch V, Losos M, Tugwell PJ. The Newcastle-Ottawa scale (NOS) for assessing the quality of nonrandomised studies in meta-analyses. *Ottawa: Ottawa Hosp Res Inst.* 2011;2(1):1-2.
17. Jadad AR, Moore RA, Carroll D, Jenkinson C, Reynolds DJ, Gavaghan DJ, et al. Assessing the quality of reports of randomized clinical trials: is blinding necessary? *Control Clin Trials.* 1996;17(1):1-12.
18. Tan Q, Wang Q, Liu D, Zhang S, Zhang Y, Li Y. Intravascular ultrasound-guided unprotected left main coronary artery stenting in the elderly. *Saudi Med J.* 2015;36(5):549.
19. Liu XM, Yang ZM, Liu XK, Zhang Q, Liu CQ, Han QL, et al. Intravascular ultrasound-guided drug-eluting stent implantation for patients with unprotected left main coronary artery lesions: A single-center randomized trial. *Anatolian J Cardiol.* 2019;21(2):83-90.
20. Agostoni P, Valgimigli M, Van Mieghem CA, Rodriguez-Granillo GA, Aoki J, Ong AT, et al. Comparison of early outcome of percutaneous coronary intervention for unprotected left main coronary artery disease in the drug-eluting stent era with versus without intravascular ultrasonic guidance. *Am J Cardiol.* 2005;95(5):644-7.
21. Park SJ, Kim YH, Park DW, Lee SW, Kim WJ, Suh J, et al. Impact of intravascular ultrasound guidance on long-term mortality in stenting for unprotected left main coronary artery stenosis. *Circulation: Cardiovasc Interv.* 2009;2(3):167-77.
22. de la Torre Hernandez JM, Baz Alonso JA, Gómez Hospital JA, Alfonso Manterola F, García Camarero T, Gimeno de Carlos F, et al. Clinical impact of intravascular ultrasound guidance in drug-eluting stent implantation for unprotected left main coronary disease: pooled analysis at the patient-level of 4 registries. *JACC: Cardiovasc Interv.* 2014;7(3):244-54.
23. Gao XF, Kan J, Zhang YJ, Zhang JJ, Tian NL, Ye F, et al. Comparison of one-year clinical outcomes between intravascular ultrasound-guided versus angiography-guided implantation of drug-eluting stents for left main lesions: a single-center analysis of a 1,016-patient cohort. *Patient Prefer Adherence.* 2014:1299-309.
24. Kim YH, Her AY, Rha SW, Choi BG, Shim M, Choi SY, et al. Three-year major clinical outcomes of angiography-guided single stenting technique in non-complex left main coronary artery diseases. *Inter Heart J.* 2017;58(5):704-13.
25. Tian J, Guan C, Wang W, Zhang K, Chen J, Wu Y, et al. Intravascular ultrasound guidance improves the long-term prognosis in patients with unprotected left main coronary artery disease undergoing percutaneous coronary intervention. *Sci Rep.* 2017;7(1):2377.
26. Darmoch F, Alraies MC, Al-Khadra Y, Moussa Pacha H, Pinto DS, Osborn EA. Intravascular ultrasound imaging-guided versus coronary angiography-guided percutaneous coronary intervention: a systematic review and meta-analysis. *J Am Heart Assoc.* 2020;9(5):e013678.
27. Wang S, Liang C, Wang Y, Sun S, Wang Y, Suo M, et al. The long-term clinical outcomes of intravascular ultrasound-guided versus angiography-guided coronary drug eluting stent implantation in long de novo coronary lesions: A systematic review and meta-analysis. *Front Cardiovasc Med.* 2022;9:944143.
28. Yashasvi Chugh MD, Rupinder Buttar MD, Tak Kwan MD, Evangelia Vemmou MD, Karacsonyi J, Iliia Nikolakopoulos MD, et al. Outcomes of intravascular ultrasound-guided versus angiography-guided percutaneous coronary interventions in chronic total occlusions: a systematic review and meta-analysis. *J Invasive Cardiol.* 2022;34(4):E310-E318.

### Address for Correspondence:

**Mr. Ahmed Raheem**, Research Specialist, Department of Emergency Medicine, Aga Khan University Hospital, Karachi, Pakistan.

**Email:** [ahmed.raheem@aku.edu](mailto:ahmed.raheem@aku.edu)