

## CASE REPORT

## DREAMY COMBINATION OF SOTALOL AND FLECAINIDE FOR TREATMENT OF LONG RP TACHYCARDIA: A NEONATAL CASE REPORT

Mahmood Hosseinzadeh Maleki<sup>1</sup>, Feisal Rahimpour<sup>2</sup>

<sup>1</sup>Imam Reza Hospital, Mashhad University of Medical Sciences, <sup>2</sup>Mashhad, Iran, Mashhad University of Medical Sciences, Mashhad, Iran

Atrial Tachycardia is one of the most refractory arrhythmias in children. To manage this arrhythmia, several strategies have been introduced with varying degrees of success. We had a case of a neonatal patient with long RP tachycardia who had different antiarrhythmic drugs to control tachycardia. Eventually, recurrent episodes of tachycardia were stopped by a combination of the Flecainide and Sotalol.

**Keywords:** supraventricular tachyarrhythmia, long RP tachycardia, Flecainide, newborn, Sotalol

**Citation:** Maleki MH, Rahimpour F. Dreamy Combination of Sotalol and Flecainide for Treatment of Long RP Tachycardia: A Neonatal Case Report. Pak Heart J. 2022;55(01):86-88. DOI: <https://doi.org/10.47144/phj.v55i1.2228>

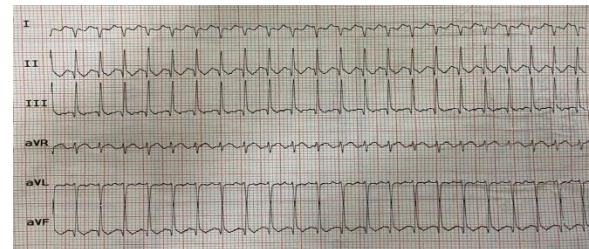
## INTRODUCTION

Ectopic Atrial Tachycardia (EAT) results from unusual focus of cells in the atria separate from the sinus node that impulsively depolarize with more speed than the underlying sinus node. Atrial Tachycardia is responsible for 4-6% of supraventricular tachycardia (SVT) which mostly is persistence and causes remarkable disorder in cardiac function.<sup>1</sup> SVT is a very common condition that requires emergency cardiac care in neonates which refers to that cases of tachycardia in which participation of at least one supraventricular structure is needed above the bifurcation of the His bundle (HB) for perpetuation. It is estimated that for every 250 to 1,000 pediatric patients, 1 case of SVT occurs.<sup>2</sup>

Sympathetic tone plays a decisive role in increase or decrease in the tachycardia rate. Typically, discrete P waves are obvious in a lengthy RP pattern.<sup>3</sup> The P wave and PR interval can provide critical information for patient management. Detailed inspection of the P wave's characteristics including morphology, amplitude, and duration, along with its association to the other components of the tracing is certainly very important for electrocardiographic diagnosis as it shows the anatomic focus of the rhythm in most cases.<sup>4</sup> The presence of first degree AV block or even Mobitz type I second-degree AV block (Wenckebach) may provide an important clue to the attendance of an abnormal Tachycardia.<sup>3</sup> Here, we describe a 16-days-old neonate with frequent episodes of SVT and the treatment method that eventually became effective.

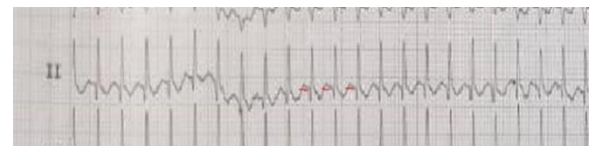
## CASE REPORT

The frequent episodes of SVT had been started when the neonate was six days old. Electrocardiogram (ECG) data suggested a narrow QRS tachycardia in the neonate (Figure 1).

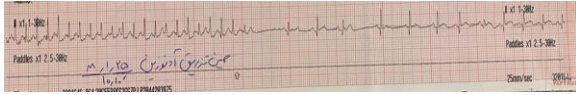


**Figure 1: ECG data which suggest a narrow QRS tachycardia**

ECG was more in favor of long RP tachycardia. In the leads aVR & II, waves were almost identical (Figure 2). Figure 3 shows AV dissociation during adenosine test that usually is compatible with long RP tachycardia. It should be noted that in reentrant tachycardia, adenosine terminates the arrhythmia and recurrence does not occur. But in the patient studied, the arrhythmia rhythm returned after a temporary reduction.

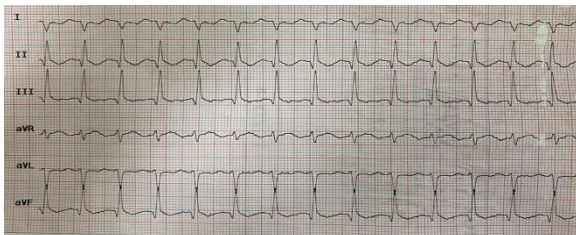


**Figure 2: lead II suggests waves were almost identical**



**Figure 3: AV dissociation during adenosine test**

Echocardiography finding and Cardiac Enzymes were normal. Inderal was started at 1mg/kg/day then increased to dose 3mg/kg/day, but long RP tachycardia was not responded to this medication. At the time of propranolol use, when the medication reached the effective dose, after a few half-lives, a tachyarrhythmia episode occurred which indicates that the treatment was ineffective. The dose of Flecainide was started at 3mg/kg/day then increased to 5mg/kg/day but we faced episodes of hemodynamic stable SVT. Propafenon was administered at dose 300 mg/m<sup>2</sup> instead of Flecainide but it was not effective. Hence, we increased its dose to 400mg/m<sup>2</sup> but it was not successful. Amiodarone was started at dose 5mg/kg instead of Propafenon but was not effective and we increased the dose to 7mg/kg but there was no achievement. Eventually, the long RP tachycardia was controlled when Sotalol (1 mg/kg/day) was used along with Flecainide (5 mg/kg/day) (Figure 4). In order to optimize the dose of medications, all the medications were started with the minimum standard dose and their dose was gradually increased. ECG findings were used to monitor toxicity of medications. Flecainide toxicity was monitored through increased PR distance and QRS duration. QT duration was used to monitor the toxicity of Sotalol. QRS duration before and after treatment was 60 and 80 milliseconds, respectively. Duration of QTc before and after treatment was 404 and 420 milliseconds, respectively.



**Figure 4: Normal sinus rhythm after the onset of Sotalol and Flecainide**

## DISCUSSION

According to the results, in presented patient, ECG was more in favor of long RP tachycardia, in the aVR& II lead waves are almost identical P wave but different from P derived from SAN which is more similar to long RP tachycardia.

There is often a difference between tachycardia and normal sinus rhythm in terms of the P-wave axis, unless it originated close to the sinus node or right superior pulmonary vein. Although even these foci

have a slightly different P-wave morphology than sinus rhythm, the ECG provides as an upright P wave in both lead I and aVF similar to normal sinus rhythm.<sup>5</sup> In the studied patient, there was positive P wave leads in I and aVF, which was a sign of origin from adjacent the sinus node or right superior pulmonary vein. As we know in PJRT (Permanent junctional reciprocating tachycardia) we see lengthy RP narrow QRS tachycardia accompanied by deeply negative P wave in leads 2,3, aVF which was not seen in our patient and the P wave was positive (but there is no certainty, because in neonate rapid rate may lead to miss diagnosis).

During adenosine test AV dissociation was seen usually in long RP tachycardia. The focal atrial rhythm was seen (Figure 3) during Adenosine test but 25-30% AT in children may response to adenosine. Also if you have accessory pathway usually after seeing adenosine delta wave, you should consider that in URAP including Permanent junctional reciprocating tachycardia there is not delta wave adenosine helpful for roll out other form of AP especially concealed form.

Arrhythmia can effect cardiac function without treatment, led to some efforts to remove EAT with catheter ablation techniques. The EAT treatment has changed dramatically using RF catheter. Larger studies demonstrating that almost 96% of EAT foci in pediatric patients can be removed through RF ablation.<sup>6,7</sup>

In a case report from Italy, Flecainide was commenced prophylactically at birth for a neonate because she had been diagnosed with episodes of SVT antenatal. The newborn patient faced with a narrow complex tachycardia 5 days after birth. According to ECG re-entry tachycardia or automatic atrial tachycardia were possible. Due to the ineffectiveness of several treatments, a wide complex tachycardia developed. Sinus rhythm reached to a stable mode by means of an increase in the daily administrations of Flecainide up to six times a day, in association with nadolol.<sup>8</sup> According to Kahr et al., the use of Sotalol and Flecainide was extraordinary effective in children requiring second line agents for treatment of supraventricular arrhythmias.<sup>9</sup>

A 2-year study conducted in Tehran, Iran, on 55 cases of infantile tachyarrhythmia showed that antiarrhythmic drugs were effective for treatment of 47 infants. Three (3) infants who had atrial flutter received cardioversion, and 3 were treated with catheter ablation. According to results of Tehran study, catheter ablation was a good choice in refractory cases.<sup>10</sup>

In a case of fetal ectopic atrial tachycardia reported from Tehran that had been diagnosed in 31 weeks of gestation, the arrhythmia was controlled by propranolol after cesarean section. In this study, Sotalol and amiodarone achieved no success in prenatal tachycardia rate control.<sup>11</sup>

In summary it can be stated that successful combination of Flecainide and Sotalol could help patient to save from risks of invasive intervention and ablation.

### AUTHORS' CONTRIBUTION

ASM: Concept and design, data acquisition, interpretation, drafting, final approval, and agree to be accountable for all aspects of the work. HS, NQ: Data acquisition, interpretation, drafting, final approval and agree to be accountable for all aspects of the work.

**Conflict of interest:** Authors declared no conflict of interest.

### REFERENCES

1. Naheed ZJ, Strasburger JF, Benson Jr DW, Deal BJ. Natural history and management strategies of automatic atrial tachycardia in children. *Am J Cardiol.* 1995;75(5):405-7.
2. Srinivasan C, Balaji S. Neonatal supraventricular tachycardia. *Indian Pacing Electrophysiol J.* 2019;19(6):222-31
3. Tracy CM, Swartz JF, Fletcher RD, Hoops HG, Solomon AJ, Karasik PE, et al. Radiofrequency catheter ablation of Ectopic atrial tachycardia using paced activation sequence mapping. *J Am Coll Cardiol.* 1993;21:910-7.
4. Borloz M. Abnormalities of the P Wave and PR Interval. *ECG in Electrocardiogram.* *Clinic Med.* 2020:383-96.
5. Salerno JC, Kertesz NJ, Friedman RA, Fenrich AL Jr. Clinical course of atrial Ectopic tachycardia is age-dependent: results and treatment in children. *J Am Coll Cardiol.* 2004;43:438-44.
6. Toyohara K, Fukuhara H, Yoshimoto J, Ozaki N, Nakamura Y. Electro-physiologic Studies and radiofrequency catheter ablation of ectopic atrial tachycardia in Children. *Pediatr Cardiol.* 2011;32:40-6.
7. Silka MJ, Gillette PC, Garson A, Zinner A. Trans-venous catheter ablation of a Right atrial automatic ectopic tachycardia. *J Am Coll Cardiol.* 1985;5:999-1001.
8. Belli G, Giovannini M, Porcedda G, Moroni M, la Marca G, Capponi G, et al. Incessant automatic atrial tachycardia in a neonate successfully treated with nadolol and closely spaced doses of flecainide: a case report. *Pediatr Rep.* 2020;12(3):108-13.
9. Kahr PC, Moffett BS, Miyake CY, Kim JJ, Valdes SO. "Second Line Medications" for Supraventricular Arrhythmias in Children: In-Hospital Efficacy and Adverse Events During Treatment Initiation of Sotalol and Flecainide. *J Cardiovasc Electrophysiol.* 2021; 32(8):2207-15.
10. Dalili M, Ajri-Khamesloo F, Madadi S, Arabi-Moghaddam MY. Infantile Tachyarrhythmia: Management Strategy and Short-Term Results in a High-Volume Referral Center. *Iran Heart J.* 2020;21(3):128-35.
11. Moghadam EA, Ghamari A, Nikoufar M. Management of Fetal Ectopic Atrial Tachycardia: What is the Best Decision?. *J Compr Pediatr.* 2018;9(1):e57734.

### Address for Correspondence:

**Dr. Feisal Rahimpour**, Associate Professor, Department of Cardiac Surgery, Imam Reza Hospital, Mashhad University of Medical Sciences, Mashhad, Iran.

**Email:** [rahimpourf1@mums.ac.ir](mailto:rahimpourf1@mums.ac.ir)