

CASE REPORT

LIGHTNING INJURY: A CASE REPORT ON CARDIAC EFFECTS OF LIGHTNING STRIKES

Atif Sher Muhammad¹, Hina Sohail¹, Nadeem Qamar¹¹National Institute of Cardiovascular Diseases (NICVD), Pakistan

Lightning strikes are rare and uncommon cause of admissions into the hospitals of Pakistan. It affects every organ of the body but cardiac effects of lightning can be benign to life threatening. This case report account a case of healthy young female, who was struck by lightning in Mithi Tharparkar, developed electrocardiographic changes and prolongation of QT interval along with moderate left ventricular systolic dysfunction with segmental wall motion abnormalities on echocardiography with positive cardiac biomarkers. Angiography was done to rule out any coronary injury but it revealed normal coronaries. We kept her on follow-up which was uneventful and these changes reverted back to normal over a course of three months.

Keywords: lightning injury, myocardial injury, electrocardiography, angiography, echocardiography

Citation: Muhammad AS, Sohail H, Qamar N. Lightning Injury: A Case Report on Cardiac Effects of Lightning Strikes. Pak Heart J. 2022;55(01):83-85. DOI: <https://doi.org/10.47144/phj.v55i1.2149>

INTRODUCTION

Lightning is a natural and unavoidable phenomenon, according to National Oceanic and atmospheric administration it is the second most common causes of natural disaster resulting mortalities after flood in United States of America. A typical lightning flash measures about 300 million volts and 30,000 Amp in contrast with a household supplying current which normally has 120 volts and 15 Amps. Temperature generates due to lightning is around 50,000°F which is higher than the surface of Sun which is 10,000°F.^{1,2}

There are various direct and indirect means by which lightning affect human lives, however, the most common and immediate cause of death from lightning is cardiac asystole and ventricular fibrillation as it causes the depolarization of whole myocardium.³ According to Unites States' National Weather Service lightning caused 40 fatalities in 2016, 17 in 2020 and 10 in 2021.¹ In Pakistan, there is a lack of research and studies related to lightning and its effect on human lives, although climate conditions of Pakistan naturally favor rain. Pakistan is also affected by global warming and climate change and it is giving more rain to Pakistan than yester decades.

CASE REPORT

During heavy rainfall and thunderstorm, a 22-year old female while sitting in her house in Mithi (Tharparkar District in the Sindh province of Pakistan) was exposed by lightning strike which fell close to her body she ran out of her house and lost her consciousness. After regaining consciousness, she complained of severe chest pain which was radiating towards her left arm, consequently she was brought to

the hospital. Her general physical examination and systemic examination were unremarkable and there were no burn marks, as lightning did not strike directly to her body. She had no past history of; chest pain, palpitations, syncope, dizziness, family history of sudden cardiac arrest, drug history or any kind of addiction. Written consent was obtained from the patient for the publications of this case report.

Differential diagnosis before investigation in the background of lightning strike includes myocardial contusion, myocardial ischemia or infarction, stress induced cardiomyopathy or anxiety related chest pain.

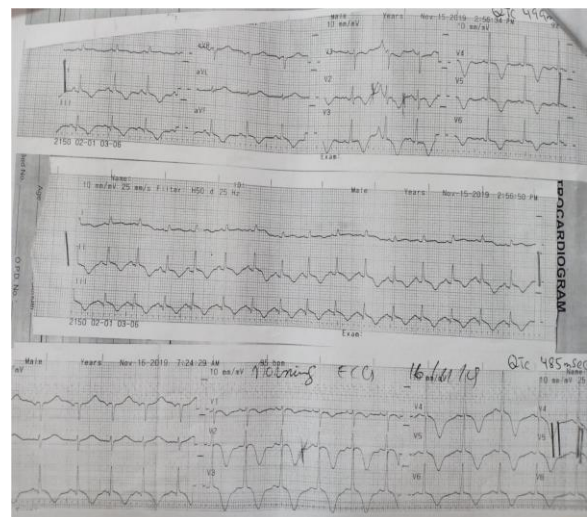


Figure 1: ECG on admission (day 1 and 2)

Initial investigations included complete blood count, urea, creatinine and electrolytes which were within normal range, Troponin-T was positive. Electrocardiogram (as illustrated in Figure 1) on

admission revealed sinus rhythm, deep T-wave inversion in anterior leads as well as in inferior leads and prolong QT interval QTc of 499ms.

Her echocardiogram showed LVEF of 35%-40% and segmental wall motion abnormality that is hypokinetic inferior and posterior wall, akinetic mid and apical anterior interventricular septum (IVS) and apex with mild to moderate mitral regurgitation (MR), mild tricuspid regurgitation (TR) and no pericardial effusion.

We kept her on ECG monitoring and started b-blocker and ACE inhibitor. Her left heart catheterization was performed to rule out any coronary injury, which showed normal coronaries. During her admission in hospital no arrhythmia or signs of heart failure were observed and she was discharged on same medications.

We kept her on follow-up and after 3 months her ECG (as illustrated in Figure 2) showed normalization of QT interval and resolution of T-wave inversion in lead II & aVF and resolution of deep T-wave inversions in anterior leads. Her echocardiogram was repeated which showed normal LV function LVEF of 55% and complete resolution of segmental wall motion abnormality and MR.

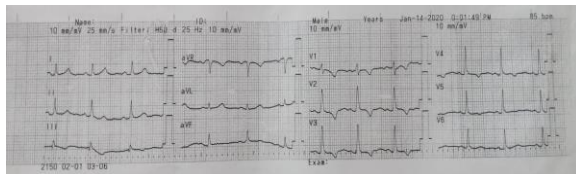

Figure 2: ECG (after 3 months)

DISCUSSION

According to NASA (National Aeronautics and Space Administration), at any given moment, more than 2,000 thunderstorms are active throughout the world producing 100 flashes per second. Every year, some 24,000 deaths, 240,000 injuries, and millions of dollars in property damage occur because of lightning.⁴ Lightning strikes are amongst the unusual causes of admission into the hospitals in Pakistan. Injuries due to lightning are various however, cardiac effects due to lightning can lead to benign to life-threatening events, including myocardial ischemia, cardiac contusion, aortic trauma, cardiomyopathies, pericardial disease and arrhythmias.

Lightning may affect victims through four common means which are described below. Indirect injuries due to lightning may be through forest and house fires, blasts and falling objects.^{3,5}

- Direct strike: when most of the current flows directly through the victim.
- Side splash: when lightning strikes an object first and then bends through the path of least resistance.
- Contact: when the victim is in contact with the metal object which gets the bolt strike.
- Ground current: when lightning strikes the ground and travels on the surface in the direction of the victim.

In this case report as houses in Tharparkar are not being modernly developed (basic rural constructions), the patient possibly sustained injury through the ground current, however side splash may possibly be involved here. Our patient developed ECG changes and segmental wall motion abnormality which were not reported previously by these means.

Lightning can directly and indirectly affect cardiac rate and rhythm. Direct effect through electrical and mechanical trauma and indirect effect by excessive catecholamine surge.⁶ Multiple ECG changes have been documented ranges from specific and nonspecific ST segment changes, T-wave inversions to prolongation of QT interval which are consistent with ischemia, contusions, pericarditis, repolarization abnormalities, and pericardial effusion.⁷ A previously healthy patient as reported by Palmer et al. developed prolongation of QT interval after lightning strike which lasted for two days and then return to normal.⁸

Tharparkar patient developed a QTc of 499 ms, which dropped down to 485 ms on the very next day. QT prolongation can be a substrate for ventricular arrhythmias. ECG monitoring in apparently stable lightning injured patients can be of paramount importance.

Patients may develop ventricular failure due to arrhythmias, cardiac ischemia and myocardial necrosis. Autonomic stimulation and excessive catecholamine surge may result in Takotsubo syndrome with apical ballooning. Though transient, this condition should not be underestimated.^{9,10} Dundon et al. reported a case of female who was struck by lightning and developed Takotsubo syndrome complicated with cardiogenic shock. In that case, the patient's cardiac function got back to normal after 6 weeks.¹¹ Similarly in 2005 Hayashi and colleagues reported a case of mountaineer she was struck by lightning and developed Takotsubo like pattern on echocardiography which was resolved in 48 hours.¹²

In our case patient develop left ventricular systolic dysfunction with wall motion abnormality but she remain asymptomatic throughout the period of three months.

In the absence of any thromboembolic coronary occlusion myocardial ischemia and infarction have been reported due to lightning injury. S Karadas et al. reported a case of inferior wall MI as a result of lightning strike with normal coronaries.¹³ There is another case of unstable ventricular arrhythmias due to lightning injury which was managed by emergency defibrillation leading to asystole and post CPR ECG showed ST elevation in inferior leads with reciprocal changes in anterior leads, but coronary angiogram showed normal coronaries.¹⁴

In our case, there are T-wave inversions in inferior leads and deep T-wave inversions in anterior leads, troponin T is positive, segmental wall motion abnormality on echocardiography and coronary angiogram revealed normal coronaries.

Lightning injuries are uncommon natural phenomena. Injuries due to lightning can be very catastrophic. It has been concluded that it is difficult to establish association between electrocardiographic ischemic changes and underlying coronary obstruction. However, further study is required in this area to identify which patients are required to be rushed to the cathlab. Detailed history, physical examination, baseline 12-lead ECG, baseline cardiac biomarkers and prolong electrocardiographical monitoring (for ventricular arrhythmias) and assessment for sign and symptoms of hemodynamic compromise should also be included in the evaluation.

AUTHORS' CONTRIBUTION

ASM: Concept and design, data acquisition, interpretation, drafting, final approval, and agree to be

Address for Correspondence:

Dr. Atif Sher Muhammad, Senior Registrar at National Institute of Cardiovascular Diseases (NICVD), Rafiqui (H.J.) Shaheed Road, Karachi- 75510, Pakistan.

Email: dratifsher75@gmail.com

accountable for all aspects of the work. HS, NQ: Data acquisition, interpretation, drafting, final approval and agree to be accountable for all aspects of the work.

Conflict of interest: Authors declared no conflict of interest.

REFERENCES

1. US Department of Commerce, NOAA. "National Weather Service Lightning Fatalities in 2021: 10". www.weather.gov.
2. US Department of Commerce, NOAA. Lightning Safety Tips and Resources. <https://www.weather.gov/safety/lightning>
3. Jensen J. D, Jeff Thurman J, Vincent A.L. Lightning Injuries. Treasure Island (FL): StatPearls Publishing; 2021.
4. Christian HJ. Lightning primer. Global HRC NASA. Available at: https://ghrc.nsstc.nasa.gov/lightning/lightning_primer.html. Accessed on 24 November, 2020.
5. Sleiwah A, Baker J, Gowers C, Elsom D. M, Rashid A. Lightning injuries in Northern Ireland. *Ulster Med J*; 2018;87(3):168-72.
6. Hekimoglu Y, Asirdizer M, Demir U, Gur A, Etili Y, Gumus O, Kartal E. An Autopsy Series: Lightning-related Deaths in Van and Hakkâri Provinces, Turkey. *West Indian Med J*. 2021;69(1):60.
7. Panda S, Sharma SK, Panda M, Sahoo SC, Tripathy S. Spectrum of electrocardiographic & clinical manifestations among the survivors of lightning injury. *J Cardiovasc Dis Res*. 2021;12(3):641-8.
8. Palmer AB. Lightning injury causing prolongation of the QT interval. *Postgrad Med J*. 1987;63(744):891-4.
9. Blumenthal R. Injuries and deaths from lightning. *J Clin Pathol*. 2021;74:279-84.
10. Christophides T, Khan S, Ahmad M, Fayed H, Bogle R. Cardiac Effects of Lightning Strikes. *Arrhythm Electrophysiol Rev*. 2017;6(3):114-7.
11. Dundon BK, Puri R, Leong DP, Worthley MI. Takotsubo cardiomyopathy following lightning strike. *Case Reports*. 2009;2009:bcr0320091646.
12. Hayashi M, Yamada H, Agatsuma T, Nomura H, Kitahara O. A case of takotsubo-shaped hypokinesis of the left ventricle caused by a lightning strike. *Int Heart J*. 2005;46(5):933-8.
13. Karadas S, Vuruskan E, Dursun R, Sincer I, Gonullu H, Akkay E. Myocardial infarction due to lightning strike. *J Pak Med Assoc*. 2013;63(9):1186-8.
14. Saglam H, Yavuz Y, Yurumez Y, Ozkececi G, Kilit C. A case of acute myocardial infarction due to indirect lightning strike. *J Electrocardiol*. 2007;40(6):527-30.