

NEW ONSET ATRIAL FIBRILLATION IN AN ELDERLY PATIENT PRESENTING WITH ACUTE DENGUE FEVER- A CASE REPORT

Syeda Hira Naqvi¹, Ghulam Hussain Soomro¹

¹ Ziauddin Hospital Clifton, Karachi, Pakistan

Address for Correspondence:

Dr. Syeda Hira Naqvi
Ziauddin Hospital Clifton, Karachi, Pakistan.

Email: hiranaqvi95@gmail.com

Contribution

SHN and GHS conceived the idea of the case report. Data collection and manuscript writing was done by SHN and GHS. All the authors contributed equally to the submitted manuscript.

All authors declare no conflict of interest.

This article may be cited as: Naqvi SH, Soomro GH. New Onset Atrial Fibrillation in an Elderly Patient Presenting with Acute Dengue Fever- A Case Report. Pak Heart J 2021;54(01):116–119.

<https://doi.org/10.47144/phj.v54i1.2074>

ABSTRACT

Dengue fever is one of the most prevalent viral diseases transmitted by mosquitoes and may cause cardiac abnormalities such as AV blocks and ectopic ventricular beats. Atrial fibrillation, however, is not common. We report a case of an 81 year old female without any structural heart disease or comorbidities, who presented with symptoms of atrial fibrillation 2 days after being diagnosed with Dengue fever. Rate controlling agents were given and a normal sinus rhythm was spontaneously achieved, which she maintained even on follow up 2 weeks later.

Keywords: dengue virus, atrial fibrillation, anticoagulants

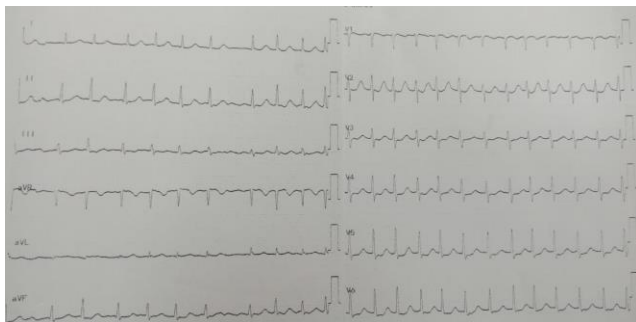
INTRODUCTION

Dengue virus causes clinical disease in 96 million cases annually making it the most prevalent viral disease transmitted by mosquitoes.¹ It is transmitted by the bite of *Aedes Aegypti* mosquito and is endemic in tropical and subtropical areas. Symptoms can vary from fever, headache, retro-orbital pain, rash, myalgia, and arthralgia to thrombocytopenia, bleeding tendency and rarely circulatory shock in patients with dengue hemorrhagic fever/dengue shock syndrome.² Cardiac manifestations including arrhythmias such as atrioventricular blocks and ectopic ventricular beats have also been reported previously; however, atrial fibrillation is uncommon in Dengue.³ After taking due consent from the patient, we report a rare case of acute atrial fibrillation in an 81 year old patient recently diagnosed with Dengue viral fever in the absence of any structural heart disease or known comorbidities.

CASE REPORT

In October 2019, an 81 year old female, presented to the Ziauddin Hospital Emergency Department in Karachi with complaints of high grade fever since 1 week, and nausea, sweating and palpitations since the past 1 hour. She was diagnosed with Dengue viral fever 2 days ago on the basis of a positive Dengue NS 1 antigen test. Her past medical history was not significant for any other medical conditions or hospital admissions.

Figure 1: ECG showing atrial fibrillation with rapid ventricular rate



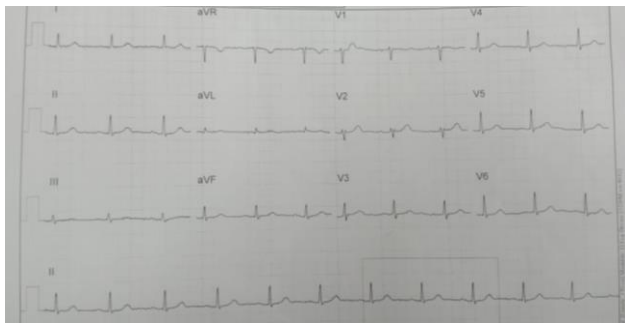On arrival to the E.R, she had an irregularly irregular pulse of 143 bpm, blood pressure was 121/76 mm Hg, respiratory rate was 25/min, SpO₂ 98%, and she was afebrile at the time. Chest examination revealed harsh vesicular breathing with bilateral equal air entry and no added breath sounds. Rest of the systemic examination was unremarkable. A 12 lead electrocardiogram (ECG) was done upon arrival which showed atrial fibrillation with a rapid ventricular rate along with ST depression (Figure 1). Troponin I was negative. An intravenous beta blocker was given and the patient was shifted to the ward once the heart rate was controlled.

Further laboratory work up revealed hemoglobin 12.3 g/dl, hematocrit 39%, total leukocyte count $3.1 \times 10^9 /L$ and platelets $210 \times 10^9/L$. Blood chemistry, and repeat troponin levels were within normal range. Echocardiography showed an ejection fraction of 60%, left ventricular diastolic dysfunction grade 1, with mild mitral regurgitation, mild tricuspid regurgitation and mild pulmonary arterial hypertension. No structural cardiac abnormalities were noted.

She was managed along the lines of Dengue viral fever and atrial fibrillation with rapid ventricular rate. During hospital admission, she was given aspirin, beta blockers, paracetamol, and proton pump inhibitors. The next day, her ECG showed a normal sinus rhythm (Figure 2). She was then discharged on aspirin, a betablocker, a statin and an angiotensin receptor blocker.

Follow up was advised after 2 weeks, once the acute febrile illness had passed, because her CHA₂DS₂ VASc score was 3 and oral anticoagulant therapy was indicated. On follow up, she was again found to have a normal sinus rhythm on ECG. She was advised to continue previous medications and was counseled regarding the need for anticoagulation. Although she agreed to continue the previously prescribed treatment, she refused anticoagulant therapy at the time.

Figure 2: ECG showing a normal sinus rhythm



DISCUSSION

It is uncommon for Dengue to cause cardiac manifestations. However, rhythm disorders have been reported previously.⁴ Yusoff K et.al reported that abnormalities in the ECG as a result of dengue infection ranged between 34-75%.⁵ However, atrial fibrillation of acute onset during the infection has rarely been reported.³ In 2018, Pranata et.al reported two cases of atrial fibrillation in dengue fever. The first case had spontaneous conversion to normal sinus rhythm before hospital discharge whereas in the second case, the patient developed persistent atrial fibrillation. Both patients were given rate controlling agents and chemical cardioversion was avoided during the hospital stay.⁶

In our case, the patient was a known case of Dengue, which was confirmed on antigen testing. We believe that the atrial fibrillation was solely a result of the Dengue infection as the patient had no predisposing risk factors such as structural heart disease as proven by the echocardiography. She also had no known comorbidities, no prior history of chest pain, palpitations etc. and no electrolyte imbalance was seen that could be identified as a possible cause of the arrhythmia. Similar principles of management were applied as mentioned by Pranata et.al, and no medical cardioversion was attempted as 50% of cases convert to sinus rhythm spontaneously after resolution of illness.⁷ The patient was kept under observation and her pre-discharge ECG showed a normal sinus rhythm.

Anticoagulant therapy was not given in the acute phase of illness due to increased risk of hemorrhagic complications in Dengue. However, atrial fibrillation causes formation of thrombi in the atria leading to an increased risk of peripheral thromboembolism and/or stroke.⁸ Therefore, once the patient was discharged, she was advised anticoagulant therapy and a direct factor Xa inhibitor was suggested. Despite the

patient's refusal to use any anticoagulant agents, we believe that anticoagulant therapy should be started once the acute phase of the disease is over and the risk of bleeding as a result of Dengue itself is minimal.

In conclusion, it must be kept in mind that patients with Dengue fever can present with uncommon cardiac manifestations such as atrial fibrillation. In such cases, patients should be monitored during the hospital stay and on follow up, for spontaneous resolution or progression to persistent atrial fibrillation. Once the acute phase of febrile illness is over and the risk of hemorrhagic complications has decreased, the need for long term anticoagulant therapy must be assessed and the patient should be managed accordingly.

REFERENCES

1. Virk H, Inayat F, Rahman Z. Complete heart block in association with dengue hemorrhagic fever. *Korean Circ J.* 2016;46(6):866.
2. Miranda CH, Borges Mde C, Schmidt A, Pazin-Filho A, Rossi MA, Ramos SG, et al. A case presentation of a fatal dengue myocarditis showing evidence for dengue virus-induced lesion. *Eur Heart J Acute Cardiovasc Care.* 2013;2(2):127-30
3. Horta Veloso H, Ferreira Júnior JA, Braga de Paiva JM, Faria Honório J, Junqueira Bellei NC, Vincenzo de Paola AA. Acute atrial fibrillation during dengue hemorrhagic fever. *Braz J Infect Dis.* 2003;7(6):418-22.
4. Nimmagadda SS, Mahabala C, Bolor A, Raghuram PM, Nayak UA. Atypical Manifestations of Dengue Fever (DF) - Where Do We Stand Today. *J Clin Diagn Res.* 2014;8(1):71-3
5. Yusoff K, Roslawati J, Sinniah M, Khalid B. Electrocardiographic and echocardiographic changes during the acute phase of dengue infection in adults. *J HK Coll Cardiol.* 1993;1:93-6.
6. Pranata R, Wiharja W, Damay V. Atrial Fibrillation in Dengue Infection: A Self-limiting Phenomenon? (Two Case Reports). *ACI (Acta Cardiol. Indones.).* 2018;4(1):36.
7. Bhatia V, Parida AK, Arora P, Mittal A, Pandey AK, Singh G et al. Electrocardiographic and echocardiographic findings during the recent outbreak of viral fever in National Capital Region. *Indian Heart J.* 2007;59(4):360-2

8. January C, Wann L, Alpert J, Calkins H, Cigarroa J, Cleveland J, et al. 2014 AHA/ACC/HRS Guideline for the Management of Patients with Atrial Fibrillation. J Am Coll Cardiol. 2014;64(21):e1-76.