

0.034” GUIDEWIRE ENTRAPMENT DURING RADIAL APPROACH FOR CORONARY ANGIOGRAPHY. A RARE COMPLICATION

Noor Dastgir¹, Ahsan Iqbal¹, Arslan Masood¹, Zubair Akram¹

<https://doi.org/10.47144/phj.v53i1.1756>

1. Allama Iqbal Medical College / Jinnah Hospital, Lahore

Address for Correspondence:

Noor Dastgir
Allama Iqbal Medical College /
Jinnah Hospital, Lahore
Emails: noordastgir@gmail.com

Contribution

ND conceived the idea of the case report. Data collection and manuscript writing was done by AI, AM and ZA. All the authors contributed equally to the submitted manuscript.

All authors declared no conflict of interest.

This article may be cited as:

Dastgir N, Iqbal A, Masood A, Akram Z. 0.034” Guidewire Entrapment during Radial Approach for Coronary Angiography. A Rare Complication. Pak Heart J 2020;53(01):88-91.

ABSTRACT

The radial artery approach for cardiac catheterization has now become the preferred route for arterial access. The main reason behind this is reduced access site complications as compared to femoral artery punctures. Radial artery access also allows the advantage of early mobilization of the patient and improved patient comfort. Lesser complications in turn result in shorter hospital stay and discharge on the same day is also possible. This in turn significantly decreases the overall cost and bed occupancy as well. However, as with every procedure complications do occur and it is how we deal with them defines our success. This is a case report in which a 0.034” radial guidewire used routinely for angiography was entrapped and how it was then tackled and recovered.

INTRODUCTION:

Cardiac catheterization was first performed in 1929 by Werner Forssmann on himself. Selective coronary angiography was described by Mason Sones in the early 1960s¹. Cardiac catheterization has evolved over a long time into its current form. Even though the first trans-radial angiography was reported by Campeau et al in 1989,² it was followed up very quickly by the first trans-radial coronary artery stenting by Kiemeneij and Laarman in 1993.³

The radial artery approach for cardiac catheterization in recent days has become more favorable in the hands of experienced operators. The main reason behind this is reduced access site complications as compared to femoral artery punctures.⁴⁻⁶ Radial artery access also allows the advantage of early mobilization of the patient and improved patient comfort. Lesser complications in turn result in shorter hospital stay. Discharge on the same day is also possible that decreases the overall cost significantly.^{7,8} Patients themselves prefer the radial route due to the convenience and follow up care. In RIVAL study 90% of the patients who had undergone cardiac catheterization through radial approach reported preference for same approach if there was any need of repeat catheterization.⁹ However, radial artery catheterization like the femoral is not devoid of any complications. We present a case of 0.034" guidewire entrapment in radial artery during coronary angiography.

CASE PRESENTATION

55 years old, diabetic female with an increasing frequency of angina was planned for coronary angiography. Radial artery access was planned for the procedure after a positive modified Allen's test. Under aseptic measures, 6 F radial artery sheath was passed and a 0.35" J tip guide wire was advanced through the sheath into radial artery. Just after crossing the forearm, the wire was unable to advance any further. Fluoroscopy of the fore arm showed the wire had taken an abnormal path just before brachial artery.

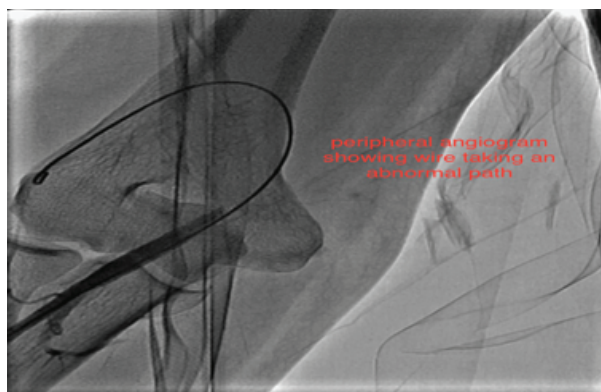


Figure 1 – showing that the wire has taken an abnormal path

An attempt to retrieve the wire was made through gentle traction however it was extremely painful for the patient so an alternate approach was considered. A 6 F JR diagnostic catheter was subsequently passed over the wire up to the limit to which it could be steered into the artery but it did not track the whole way. Another attempt to retrieve the wire was made with the support of the catheter but this also proved unsuccessful (Figure 2).

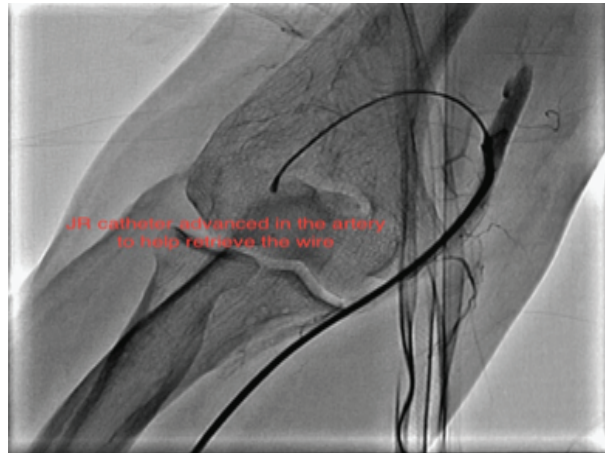
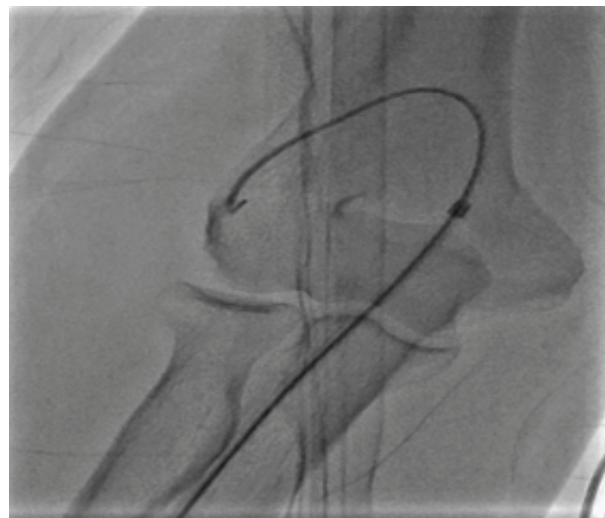


Figure 2 – A JR Catheter advanced over the wire for support

In order to rule out perforation of the radial artery a peripheral angiogram was performed which confirmed that the wire had taken an abnormal turn into a branch but fortunately there was no perforation. Intra-arterial nitroglycerine up to 500 mcg was given to relieve any radial artery spasm followed by another attempt at retrieval of the



wire under fluoroscopy but to no benefit. A 4 F glide catheter [Terumo GLIDECATH] was then advanced on the wire into the side branch and finally this proved to be successful and the wire was retrieved through it. (Figure 3)

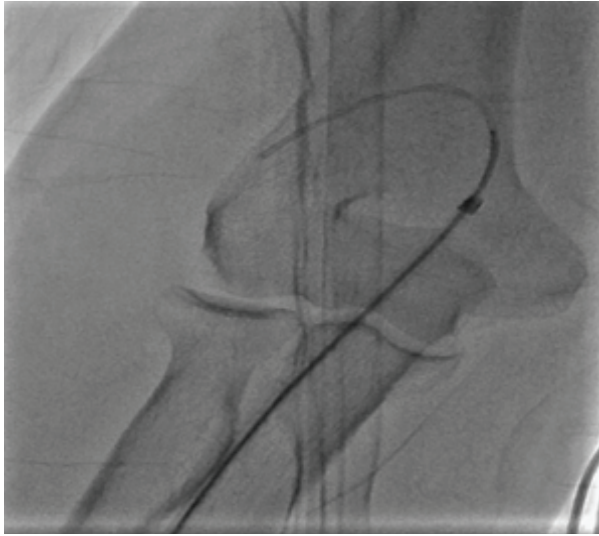


Figure 3- the wire finally being retracted through a 4F glide catheter

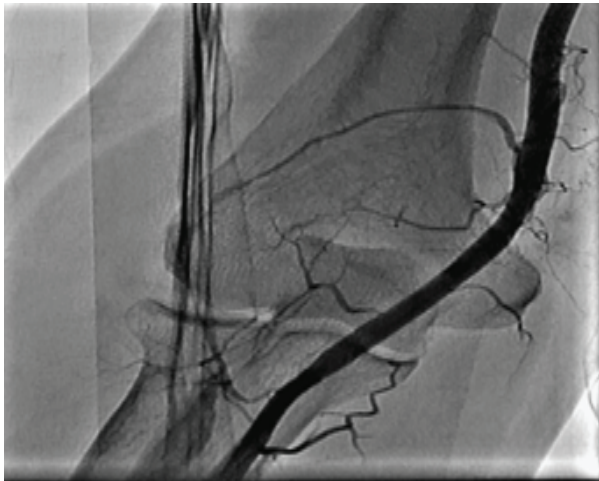

Figure 4: Normal flow established

DISCUSSION:

Radial artery access is quickly becoming the preferred route of intervention, as more and more operators are becoming familiar with it. It is associated with a decreased incidence of bleeding and other access site complications when compared with the femoral artery approach. A common complication associated with radial artery catheterization is radial artery spasm that can result in catheter entrapment or sheath entrapment.¹⁰ A few cases of radial artery avulsion due to entrapment of radial sheath have also been reported.¹¹ As far as the guiding wires are concerned, the usual cases reported are of 0.014" guide wire entrapment in coronary arteries during percutaneous coronary interventions (PCI)

0.034" Guidewire entrapment in radial artery however, as seen in our case is a rare phenomenon. Luckily, there was no further complications due to it but the entrapped guidewire could have resulted in perforation of the main radial artery or of one of the branches where it got stuck. Secondly a fragment of the wire may also fracture and get further entrapped in one of the side branches causing occlusion of that branch.

However, if such a complication does arise, there are multiple approaches that may be taken towards its management. One way is to simply apply gentle force to retrieve the wire under fluoroscopy. Localized intra-arterial vasodilators such as verapamil or nitroglycerine may be used in order to relieve radial artery spasm. Even continuous intravenous infusion of nitroglycerine 0.1mcg/kg/min can be administered in cases with severe arterial spasm according to the hemodynamics of the patient. A glide catheter can also be used as was done in our case to retrieve the wire. If all such medical and local efforts fail, then the only option left is to go for surgical retrieval of the wire.

REFERENCES:

1. Bourassa MG1. The history of cardiac catheterization. *Can J Cardiol* 2005;21(12):1011-4
2. Campeau L. Percutaneous radial artery approach for coronary angiography. *Cathet Cardiovasc Diagn* 1989;16(1):3-7.
3. Kiemeneij F, Laarman GJ. Percutaneous transradial artery approach for coronary stent implantation. *Cathet Cardiovasc Diagn* 1993;30(2):173-8.
4. Agostoni P, Biondi-Zoccai GG, de Benedictis ML, Rigattieri S, Turri M, Anselmi M. Radial versus femoral approach for percutaneous coronary diagnostic and interventional procedures; Systematic overview and meta-analysis of randomized trials. *J Am Coll Cardiol* 2004;44(2):349-56.
5. Rao SV, Ou FS, Wang TY, Roe MT, Brindis R, Rumsfeld JS. Trends in the prevalence and outcomes of radial and femoral approaches to percutaneous coronary intervention: a report from the National Cardiovascular Data Registry. *JACC Cardiovasc Interv* 2008;1(4):379-86.
6. Jolly SS, Amlani S, Hamon M, Yusuf S, Mehta SR. Radial versus femoral access for coronary angiography or intervention and the impact on major bleeding and ischemic events: a systematic

review and meta-analysis of randomized trials. *Am Heart J* 2009;157(1):132-40.

7. Jabara R, Gadesam R, Pendyala L, Chronos N, Crisco LV, King SB. Ambulatory discharge after transradial coronary intervention: Preliminary US single-center experience (Same-day TransRadial Intervention and Discharge Evaluation, the STRIDE Study). *Am Heart J* 2008;156(6):1141-6.
8. Cooper CJ, El-Shiekh RA, Cohen DJ, Blaesing L, Burket MW, Basu A. Effect of transradial access on quality of life and cost of cardiac catheterization: A randomized comparison. *Am Heart J* 1999;138(3 Pt 1):430-6
9. Jolly SS, Yusuf S, Cairns J, et al. Radial versus femoral access for coronary angiography and intervention in patients with acute coronary syndromes (RIVAL): a randomised, parallel group, multicentre trial. *Lancet* 2011;377(9775):1409-20
10. Kim JY1, Moon KW, Yoo KD. Entrapment of a kinked catheter in the radial artery during transradial coronary angiography. *J Invasive Cardiol* 2012;24(1):E3-4.
11. V Kumar V, Kumar A, Vaddera S. Avulsion of radial artery during coronary angiogram – A case report. *IHJ Cardiovascular Case Reports* 2017;1(2):80-82.