

IMPLANTATION OF WATCHMAN DEVICE TO CLOSE LEFT ATRIAL APPENDAGE USING LEFT FEMORAL VEIN APPROACH

Naseer Ahmed¹, Giulio Molon², Guido Canali³, Patrizio Mazzone⁴, Laura Lanzoni⁵, Alessio Rungatscher⁶, Enrico Barbieri⁷, Giuseppe Faggian⁸

¹Department of Biological & Biomedical Sciences, Aga Khan University, Karachi - Pakistan

^{2,3,5,7}Cardiology department, Sacro-cuore Hospital, Via Don A. Sempredoni Negrar, Verona- Italy

⁴ Unità Operativa di Aritmologia ed Elettrofisiologia cardiac Settore Q, 4° piano Ospedale San Raffaele, Istituto di Ricovero e Cura a Carattere Scientifico, Via Olgettina, Milano- Italy

^{6,8}Division of Cardiac Surgery, University of Verona, Medical School, Via Stefani, Verona- Italy

Address for Correspondence:

Naseer Ahmed,

Department of Biological & Biomedical Sciences, Aga Khan University, Karachi - Pakistan

E-mail: dr.naseer99@gmail.com

Date Received: March 09, 2017

Date Revised: September 16, 2017

Date Accepted: November 28, 2017

Contribution

NA wrote the manuscript and assisted in procedure. GM, GC, PM, EB did Intervention for LAA closure LL performed TE-echocardiography. GF reviewed the case report. All authors contributed significantly to the submitted manuscript.

Case report have been presented and abstract published in meeting proceeding in "How to Close LAA" meeting in Frankfurt, Germany.

This article may be cited as: Ahmed N, Molon G, Canali G, Mazzone P, Lanzoni L, Rungatscher A, Barbieri E, Faggian G. Left atrial appendage closure by using left femoral vein approach. Pak Heart J 2018; 51 (01): 91-3.

ABSTRACT

An 83 years old patient with permanent Atrial Fibrillation (AF) and bleeding disorders was referred for Left Atrial Appendage (LAA) closure. The LAA closure device was successfully implanted using the left femoral vein approach as the right femoral vein was occluded. The trans septal puncture and implantation of the LAA closure device were guided by fluoroscopic and transesophageal echocardiographic images. There were no complications. Trans septal puncture guided by a combination of fluoroscopic and transesophageal echocardiographic imaging can be safely carried out using the left femoral vein approach as an alternative option when the right femoral vein is not accessible.

Key Words: Left Atrial Appendage, Trans-septal puncture, Atrial Fibrillation, Left femoral vein approach, Trans-esophageal echocardiography.

INTRODUCTION

Atrial Fibrillation (AF) is the most common tachyarrhythmia and is associated with major complications such as thromboembolic events. Anticoagulation therapy remains an important component of AF treatment to avoid thromboembolism. Left Atrial Appendage (LAA) closure may be considered in patients with AF with high stroke risk and contraindications for long term oral anticoagulation. Devices for LAA closure are usually implanted through trans-septal puncture by using the right femoral vein (RFV). Alternative approaches for accessing the left atrium have been reported, but there are no reports on usage of the left femoral vein (LFV) for LAA closure by using watchman device, that is unusual for septal puncture.²⁻⁷ In this report, we describe a LAA closure in an 83 year old patient using the LFV approach.

CASE REPORT

A 83 years old male patient, with permanent AF with CHADS₂ score 3, gastrointestinal bleeding (HAS-BLED = 5) was admitted at our hospital. The medical history included myocardial infarction, percutaneous coronary angioplasty, dilated ischemic cardiomyopathy, moderate left ventricular

dysfunction, NYHA class II, moderate renal failure and hypertension. The patient was considered a candidate for LAA closure using a Watchman device in order to avoid oral anticoagulation (OAC) therapy, according to current guidelines. During the procedure, RFV access was hampered by deployment of right common iliac vein towards left side (Figure 1).

We therefore decided to puncture the interatrial septum using a LFV approach, guided by simultaneously fluoroscopic and Trans-Esophageal Echocardiographic imaging (TEE).

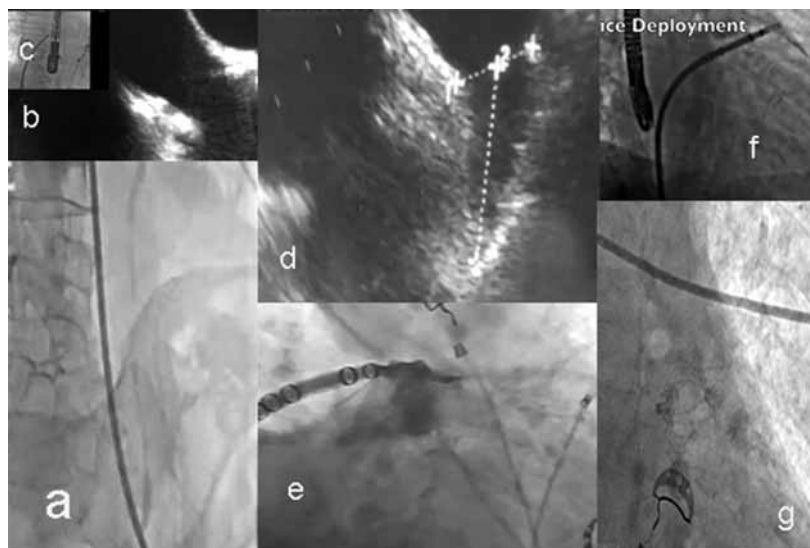
Classically, the puncture site is reached by pulling the TS sheath down into the right atrium and Fossa Ovalis (FO) respectively while observing the two drop movement. When using the LFV approach, this maneuver is very difficult and

usually unsuccessful, particularly due to the angulation at the junction between the left common iliac vein and inferior vena cava. This angulation turns the needle away from the interatrial septum, thus hampering good contact with the wall of FO. In our case, we were unable to see the two drop movements into the right atrium and FO even when using needles with different curves. We then combined fluoroscopic and TEE images to confirm the exact position of the TS sheath and subsequently steer it into the FO (Figure 2). Using this approach we successfully performed TS puncture and implanted the Watchman device (Figure 2). There were no complications and the patient was discharged on the third postoperative day. After two years of follow-up the patient remained asymptomatic, free of OAC therapy and without any cerebrovascular events.

Figure 1: Computed Tomography Angiographic Image of Pelvis Illustrating the Vascular Anatomy.

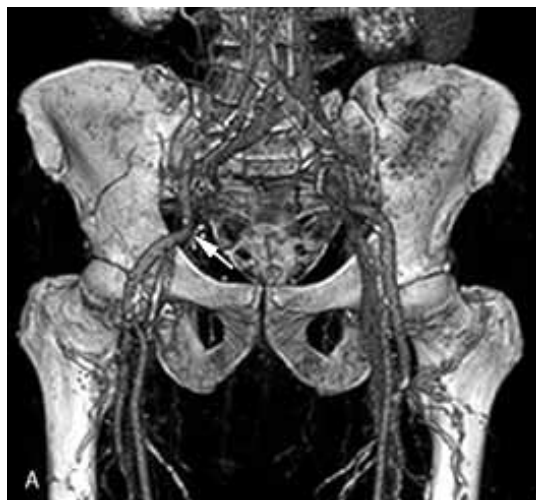

Figure 2: The TEE Views Showing the Site of the Trans-Septal Puncture and the LAA Measurements (a, c). Insertion Of The Trans-Septal Sheath Using The Left Femoral Vein (e). Fluoroscopic View of the Puncture Site, Insertion, Deployment And The Implanted Device In Laa (b,d,f,g).



DISCUSSION

According to our knowledge, we reported for the first time a watchman device implantation using the left femoral vein approach. Only a few cases have been reported in which other routes to the left atrium were described including the trans jugular and LFV approach. These approaches were used for percutaneous transvenous mitral commissurotomy, mitral balloon valvulotomy and ablative therapy. However, the two drop movement cannot be seen when using these approaches and we therefore preferred the LFV approach. This two drop movement is helpful for localizing the fossa ovalis, but for accurate determination, the aid of simultaneous fluoroscopic and TEE imaging facilitates identification of the puncture site. This case shows that the LFV approach can be used safely to perform left sided procedures including devices implantation.

CONCLUSION

TS puncture guided by a combination of fluoroscopic and TEE images can be safely carried out by using the LFV approach as an alternative option when the RFV is not accessible.

REFERENCES

1. Baim DS. Percutaneous approach, including transseptal and apical puncture. In: Baim DS, Grossman W, editors. *Cardiac catheterization, angiography and intervention*. 5th ed. London: Williams & Wilkins; 1996:73-82
2. Martinez CA, Moscucci M. Transseptal catheterization, atrial septostomy, and left ventricular apical puncture. In: Moscucci M, editor. *Complications of cardiovascular procedure: risk factors, management, and bailout techniques*. Philadelphia: Wolters Kluwer; 2011. p. 321-42.
3. Joseph G, Baruah DK, Kuruttukulam SV, Chandy ST, Krishnaswami S. Transjugular approach to transseptal balloon mitral valvuloplasty. *Cathet Cardiovasc Diagn* 1997;42(2):219-26.
4. Patel TM, Dani SI, Rawal JR, Shah SC, Patel TK. Percutaneous transvenous mitral commissurotomy using Inoue balloon catheter: a left femoral vein approach. *Cathet Cardiovasc Diagn* 1995;36(2):186-7.
5. Shalghanov TN, Traykov VB, Aleksieva KA. Transseptal access to the left atrium from the left femoral vein. *Rev Esp Cardiol* 2008;61(9):988-9.
6. Ebrahimi M, Eshraghi A. Percutaneous mitral balloon valvulotomy using left femoral vein; an unusual case. *Int Cardiovasc Res J* 2013;7(2):75-6.
7. Vyas C, Shah S, Patel T. Percutaneous transvenous mitral commissurotomy via left femoral vein approach--exploring an unusual approach for left atrial entry. *J Invasive Cardiol* 2011;23:145-6
8. Reddy VY, Doshi SK, Sievert H, Buchbinder M, Neuzil P, Huber K, et al. Percutaneous left atrial appendage closure for stroke prophylaxis in patients with atrial fibrillation: 2.3-Year Follow-up of the PROTECT AF (Watchman Left Atrial Appendage System for Embolic Protection in Patients with Atrial Fibrillation) Trial. *Circulation* 2013;127(6):720-9.
9. Bayrak F, Chierchia GB, Namdar M, Yazaki Y, Sarkozy, de Asmundis C, et al. Added value of transoesophageal echocardiography during transseptal puncture performed by inexperienced operators. *Europace* 2012;14:661-5.
10. Fisher TF. Transseptal puncture. In: Colombo A, Stankovic G, editors. *Problem oriented approaches in interventional cardiology*. New York: CRC Press; 2007. p. 203-18.