

## VARIED PRESENTATIONS OF ACUTE PULMONARY EMBOLISM

Zakariya Irfanullah<sup>1</sup>, Rizwan Khan<sup>2</sup>, Zia ud Deen<sup>3</sup>, Syed Ijlal Ahmed<sup>4</sup>, Syeda Beenish Bareeqa<sup>5</sup>,  
Syeda Sana Samar<sup>6</sup>, Asiya Jatoi<sup>7</sup>, Sultana Habib<sup>8</sup>

<sup>1,7,8</sup> Ziauddin Medical University, Karachi - Pakistan

<sup>2</sup> National Institute of Cardiovascular Diseases, Karachi - Pakistan

<sup>3</sup> DOW Medical College, DOW University of Health Sciences, Karachi - Pakistan

<sup>4</sup> Liaquat National Medical College and Hospital, Karachi - Pakistan

<sup>5</sup> Jinnah Medical and Dental College, Karachi - Pakistan

<sup>6</sup> Jinnah Sindh Medical University, Karachi - Pakistan

Address for Correspondence:

**Syed Ijlal Ahmed,**

Liaquat National Medical College and Hospital, Karachi - Pakistan

E-mail: syedijlahmed@gmail.com

Date Received: July 26, 2017

Date Revised: October 26, 2017

Date Accepted: December 19, 2017

### Contribution

IA, ZI, conceived the idea, RK, ZUD, SIA, SBB, SSS wrote manuscript. RK & ZUD helped in data gathering. AJ & SH helped in picture acquisition & data gathering. All authors contributed equally to the submitted manuscript.

**All authors declare no conflict of interest.**

This article may be cited as: Irfanullah Z, Khan R, Deen ZU, Ahmed SI, Bareeqa SB, Samar SS, Jatoi A, Habib S. Varied presentations of acute pulmonary embolism. Pak Heart J 2018; 51 (01):86-90.

### ABSTRACT

Acute pulmonary embolism (APE) is a common disease which can be potentially fatal unless treated promptly. APE can present with a wide clinical severity, ranging from asymptomatic to RV failure— ultimately leading to death. This variable presentation often hinders the timely diagnosis and management of PE, thereby increasing mortality. Immediate diagnosis and prompt, effective therapy significantly decreases the mortality rate. Here, we describe three patients who presented with varying symptoms and were ultimately diagnosed with PE. In all three cases, the major underlying risk factor was prolonged immobilization (due to either hospitalization or due to their profession) and all were treated immediately following diagnosis. This article emphasizes the importance of keeping a high index of clinical suspicion for pulmonary embolism in immobilized patients, rapid diagnostic workup and immediate treatment of patients presenting with PE along with adequate counseling.

**Key words:** Acute pulmonary embolism, Immobility, Posture

### INTRODUCTION

Venous thrombo-embolism (VTE) – including deep vein thrombosis (DVT) and PE – is the third most frequent existing CV disease.<sup>1</sup> The trial study SMART emphasizes the high mortality and prevalence of DVT in Asian countries.<sup>2</sup> However, in Pakistan it is one of the most unrecognized, undetected and undertreated clinical conditions.<sup>3</sup> Acute VTE can lead to sudden death due to massive PE. Additionally, it can cause disability or chronic disease unless immediate action is taken.<sup>4</sup> Presentation, as well as risk factors of PE, may vary from patient to patient. Immobility associated with major surgery or debilitating illness has been shown to be associated with increased risk of PE. In contrast, the association between VTE and sitting down (for example, in the 'lotus position' adopted by many tailors in Pakistan) has received very little attention. Information has been limited to the publication of a number of case reports.<sup>11</sup> Associated risk of VTE is significantly increased in both bed-ridden patients suffering from chronic disease, as well as otherwise healthy individuals who endure long periods of seated immobility in their daily routine.<sup>12</sup> Here we describe three different cases of PE with varying presentations but all having immobility as the

main risk factor. Their initial diagnostic workup, response to therapy, and prognosis is all documented to show the benefit of timely management of acute PE irrespective of the patient status.

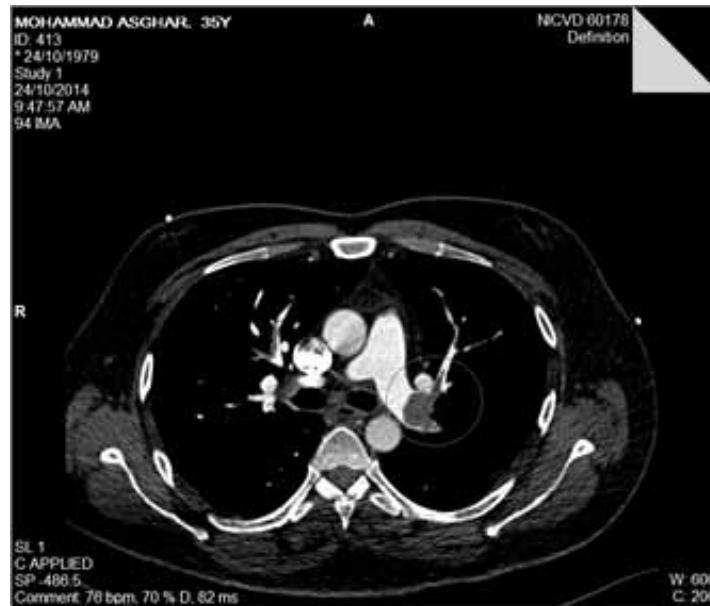
### CASE 1

Our first patient, a 35-year-old male tailor, smoker, who would sit in the crossed leg/lotus position for hours, presented to the ER with complains of dyspnea (NYHA IV) and pain in the left leg for one day which started acutely during work. Both complaints were exacerbated on exertion. The patient reported several episodes of blackout along with swelling in the left leg which increased on prolonged standing and exertion. There was no history of chest pain or syncope, and no family history of VTE. He was initially admitted and managed at another hospital as 'NSTEMI due to raised Troponin I level' and was referred to NICVD for further treatment.

Examination on admission showed his BP to be 140/100 mmHg, pulse 120 bpm regular, tachypnea with RR 40/min,

pitting edema of left lower limb up to shin along with slight hyperpigmentation, raised JVP and intact peripheral pulses. ECG showed RBBB with sinus tachycardia and RV strain pattern. D-dimer was found raised (1.8 mg/dL), while Echo disclosed enlarged RV with dysfunction (RV size 26mm), moderate TR, normal LV size and function (EF 67%) and PAP of 30mmHg. For confirmation, the patient underwent CT pulmonary angiography. This revealed filling defect in left PA and its branches and intrapulmonary segments of right PA, consistent with PE (Figure 1). Doppler U/S of both lower limbs revealed dilatation of left popliteal vein with no blood flow suggesting DVT in left popliteal vein. Intravenous Thrombolysis (Streptokinase) was given followed with intravenous heparin for one week adjusted on oral warfarin for another week. He totally settled down, and then on his request he was switched to oral Rivaroxaban twice daily. He was counseled as regard to avoidance of prolonged crossed legged posture and long standing with intermittent leg exercises. After a year on phone contact he never had those complaints again and he was withdrawn off anticoagulation.

**Figure 1: Filling Defect in Left Pulmonary Artery and Its Branches and Intrapulmonary Segments of Right Pulmonary Artery, Consistent With Pulmonary Embolism**



### CASE 2

A 33-year-old male driver taking long routes into cities-recently diagnosed hypertensive-presented with progressively worsening dyspnea on exertion for 2 weeks, with NYHA III/IV on admission. He also had left lower limb pain for the last 1 year with redness and swelling. He denied any history of chest pain, orthopnea, Paroxysmal Nocturnal Dyspnea, trauma or surgery in past. No Family history of

VTE. On admission, his BP was 90/60 mmHg, tachycardia, tachypnea, SaO2 84%, and left lower limb swelling up to his thigh. The rest of the systemic examination was unremarkable.

ECG showed sinus tachycardia. Echo disclosed moderately dilated RV with severe systolic dysfunction and severe PAH with the pressure in the pulmonary artery being 80 mm of Hg (normal being 6-12 mm of Hg), RV size of 26mm, severe TR, normal LV size and function (with LVEF 65%). The patient

underwent CT angiography which showed massive emboli in right and left pulmonary arteries. Further workup was done by Doppler U/S of both lower limbs which showed massive DVT in left lower limb involving left popliteal vein, and left femoral vein.

I/V Streptokinase were given, followed by subcutaneous Enoxaprin and oral Warfarin. His clinical status improved and he gradually became asymptomatic over time. He was advised to avoid long sitting postures along with doing frequent leg exercises. After three months, he was withdrawn off oral anticoagulation.

### CASE 3

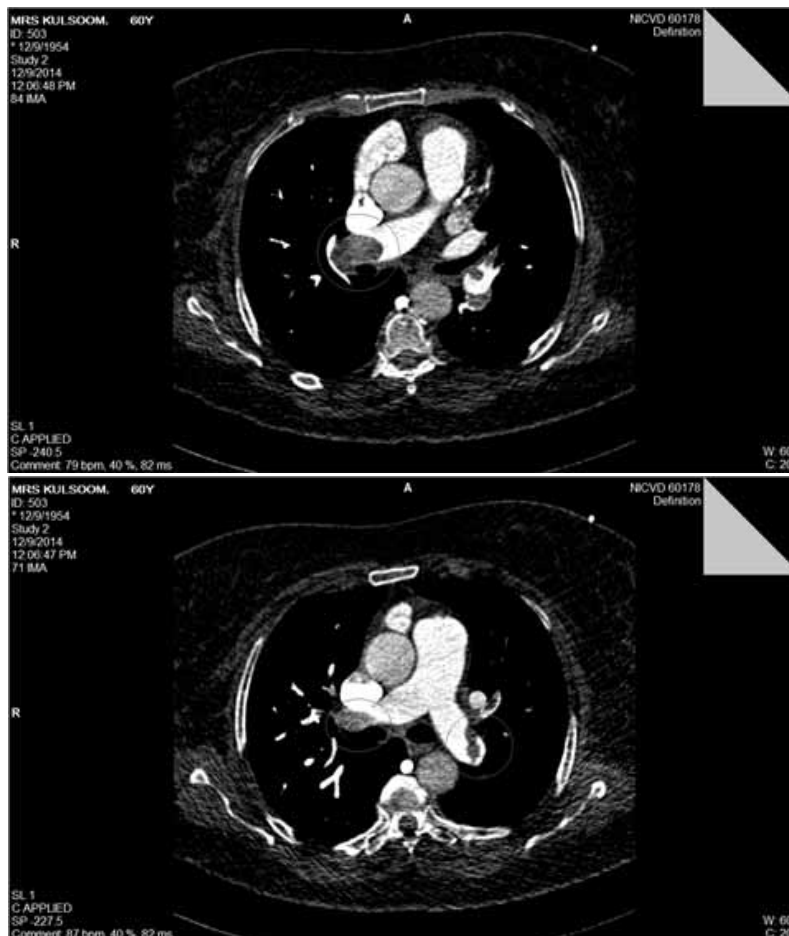
A 58-year-old female, known case of DM and HTN, presented to the ER with complains of palpitations and sweating for one day. The patient had a recent hysterectomy for a CA uterus 30 days ago. After surgery, the patient had a complicated wound rupture which confined her to prolonged bed rest. After a post surgical period of 30 days, the patient suddenly developed these symptoms. There was no

significant family history of cancer or VTE. She was admitted as a suspected case of PE.

On Examination her BP was 110/70mmHg, pulse 68/min, RR 24/min and there was abdominal tenderness and distension due to previous surgical wound. The rest of the systemic examination was unremarkable.

ECG was normal, Echo disclosed enlarged RV with severely depressed function and severe TR, RV size 26mm, normal LV size and systemic function (with EF 74%). The patient underwent CT angiography which showed filling defects in right and left pulmonary arteries and their intra-pulmonary segments due to thrombus formation, causing total obstruction of intrapulmonary segments with no calcification (Figure 2 and 3). Following this, a Doppler U/S was done of both lower limbs which showed poorly echogenic thrombus in the left popliteal vein confirming the diagnosis of DVT in left lower limb involving the left popliteal and left tibial vessels. All her coagulation profile was within normal limits.

**Figure 2 & 3: CT Pulmonary Angiography Which Showed Filling Defects In Right and Left Pulmonary Arteries and Their Intra-Pulmonary Segments Due To Thrombus Formation, Causing Total Obstruction of Intrapulmonary Segments With No Calcification**



In response, Guideline-mediated medical therapy was promptly started. I/V thrombolytic therapy (Streptokinase) was given, followed by anticoagulation with S/C Enoxaprin and oral Warfarin. The patient improved after this treatment and became asymptomatic. Initially she was discharged on S/C LMWH due to her infected wound which was dealt by the specialist and was counseled to exercise regularly. After two weeks she was switched to oral rivaroxaban. She continued this as she underwent radiotherapy for her CA uterus. She was followed up twice at 6-months and 1 year and echo showed significant reduction in PAP and RV function.

## DISCUSSION

VTE is a very common issue and has a multiplicity of causes. Its pathophysiology is quite well documented. Damage to a blood vessel, from either an injury or surgery, can provoke a blood clot. Being confined to bed during the recovery period leads to sluggish blood flow which further increases the risk. More than half the cases of VTE are related to a recent hospital stay or surgery, leading to prolonged immobilization, however, most cases don't occur until after the patient left the hospital. Undergoing treatment for cancer also raises one's risk, and this was seen in our patient. Additionally, prolonged sitting due to long-distance travel or even the crossed-leg posture very commonly seen in tailors from the subcontinent is a cause of pulmonary embolism but has never been reported. While we were reporting this, two additional tailors were admitted with PE. Hence, cases for DVT and PE are not uncommon. There is a thorough need for awareness of these risk factors in our country.

This report aims to highlight the variable presentation of PE along with their relation to specific postures, and unfortunately, the strong possibility of misdiagnosing PE on initial presentation. In certain situations, an early clinical suspicion of PE is the most important step in diagnosis and management.<sup>5</sup> Chest pain or SOB with history of seated immobility at work (and absence of alternating explanation of these symptoms) should be considered a red flag for APE and such patients should be screened out. All three of our patients were treated for other causes whereas they should have been aware of this life-threatening outcome long before.

The most useful initial test in this situation is echocardiography, which yields evidence of acute PAH and RV dysfunction in PE. In highly unstable patients, evidence of RV dysfunction is sufficient to prompt immediate reperfusion without further testing, while CT pulmonary angiography remains the gold standard test for diagnosing APE.<sup>6,7</sup>

Thrombolytic therapy, given as primary reperfusion therapy, can prevent potentially life threatening hemodynamic instability. Anticoagulation therapy to prevent early death and recurrence of fatal VTE is indicated in all patients with acute

PE for a period of at least 3 months. Acute-phase treatment consists of administering parenteral anticoagulation UFH or LMWH over the first 5–10 days. In a few cases, extended oral anticoagulation after the first 3 months, or even indefinitely, may be indicated for secondary prevention.

Thrombolytic treatment of acute PE restores pulmonary perfusion faster than using UFH alone.<sup>8</sup> The early resolution of pulmonary obstruction leads to a prompt reduction in PAP and resistance, which significantly improves RV function.<sup>9</sup> Patients who have suffered PE have a higher chance of having recurrent PE, whereas in patients who have suffered DVT, it tends to recur more frequently as DVT.<sup>10</sup>

Preventing clots in the deep veins in one's legs (deep vein thrombosis) can help prevent pulmonary embolism. For this reason, most hospitals are aggressive about taking measures to prevent blood clots, including blood thinners (anticoagulants), compression stockings, leg elevation, physical activity, keeping proper hydration and posture, and pneumatic compression. Unfortunately, non of our three patients were advise by their doctors, despite multiple visits.

## CONCLUSION

These cases illustrate the importance of educating the demographics involved in professions that require prolonged immobility (e.g. tailors and truck drivers). Additionally, doctors should have a high index of clinical suspicion for patients who present with this history. Once diagnosed, early and aggressive management can lead to a good prognosis. After the treatment, well-measured counseling can prevent PE from reoccurring.

## REFERENCES

1. Heit J A. The epidemiology of venous thromboembolism in the community. *Arterioscler Thromb Vasc Biol* 2008;28(3):370-2.
2. Leizorovicz A, Turpie AG, Cohen AT, Wong L, Yoo MC, Dans A. Epidemiology of venous thromboembolism in Asian patients thromboprophylaxis. *J Thromb Haemost* 2005;3(1):28-34.
3. Husain SJ, Zubairi AB, Fatima K, Irfan M, Atif M, Saeed MA. Clinical characteristics, management and outcome of major pulmonary embolism: an experience from a tertiary care center in Pakistan. *J Pak Med Assoc* 2009;59(6):372-5.
4. Klok FA, vanKralingen KW, van Dijk AP, Heyning FH, Vliegen HW, Kaptein AA, et al. Quality of life in long-term survivors of acute pulmonary embolism. *Chest* 2010;138(6):1432-40.
5. Heit JA, O'Fallon W, Petterson TM, Lohse CM, Silverstein MD, Mohr D, et al. Relative impact of risk factors for deep vein thrombosis and pulmonary

- embolism: a population-based study. *Arch Intern Med* 2002;162(11):1245-8.
6. Torbicki A, Galiè N, Covezzoli A, Rossi E, De Rosa M, Goldhaber SZ. Right heart thrombi in pulmonary embolism: results from the International Cooperative Pulmonary Embolism Registry. *J Am Coll Cardiol* 2003;41(12):2245-51.
  7. Ayaram D, Bellolio MF, Murad MH, Laack TA, Sadosty AT, Erwin PJ, et al. Triple rule-out computed tomographic angiography for chest pain: a diagnostic systematic review and meta-analysis. *Acad Emerg Med* 2013;20(9):861-71.
  8. Dolla Volta S, Palla A, Santolicandro A, Giuntini C, Pengo V, Visioli O, et al. PAIMS 2: alteplase combined with heparin versus heparin in the treatment of acute pulmonary embolism. Plasminogen activator Italian multicenter study 2. *J Am Coll Cardiol* 1992;20(3):520-6.
  9. Becattini C, Agnelli G, Salvi A, Grifoni S, Pancaldi LG, Enea I, et al. Bolus tenecteplase for right ventricle dysfunction in hemodynamically stable patients with pulmonary embolism. *Thromb Res* 2010;125((3):e82-e6.
  10. Murin S, Romano PS, White RH. Comparison of outcomes after hospitalization for deep venous thrombosis or pulmonary embolism. *Thromb Haemost* 2002;88(3):407-14.
  11. Beasley R, Raymond N, Hill S, Nowitz M, Hughes R. Thrombosis: the 21st century variant of thrombosis associated with immobility. *Eur Respir J* 2003;21(2):374-6.
  12. West J, Perrin K, Aldington S, Weatherall M, Beasley R. A case control study of seated immobility at work as a risk factor for venous thromboembolism. *J R Soc Med* 2008;101(5):237-43.