

## FOLLOW UP OF THE PATIENTS TREATED WITH THE MGuard STENT SYSTEM IN PERCUTANEOUS CORONARY INTERVENTION AT AFIC – NIHD

AZHAR MAHMOOD KAYANI<sup>1</sup>, SAJJAD HUSSAIN<sup>2</sup>, RUBAB MUNIR<sup>3</sup>

### ABSTRACT

The objective of this study was to conduct a follow up of the patients treated with the MGuard Stent used in Percutaneous Coronary Intervention (PCI) in the setting of acute coronary syndromes at AFIC – NIHD.

**Introduction:** The consequences of distal embolisation during PCI in acute coronary syndrome can vary from a simple sluggish flow to myocardial infarction and death. A number of protection devices reduce distal embolisation, but they add complexity and cost to the procedure. The MGuard stent is a unique innovation to counter the phenomenon.

**Objective:** The objective of this study was to conduct an angiographic follow up of the patients treated with the MGuard Stent used in Percutaneous Coronary Intervention (PCI) in the setting of acute coronary syndromes at AFIC – NIHD.

**Patients and Methods:** The study was conducted in AFIC – NIHD. Between April 2010 to date 21 patients were treated with a total of 25 MGuard stents. Inclusion criteria included de novo lesions in saphenous vein grafts or native vessels with angiographic evidence of thrombus activity or lesion instability and a potential for distal embolization, all in the setting of acute coronary syndromes.

**Results:** All patients were male. Mean age was 46.23 years (range 32-70 years). All patients were admitted with acute coronary syndromes. Most lesions had complex morphological features and all had some thrombus activity. The MGuard stent was deployed successfully in all cases and without any complications. Secondary endpoints (TIMI – III flow and myocardial blush grade 3) were met in all cases. There was no elevation of cardiac enzymes post procedure in any patient. On follow up Nine patients (42%) had critical ISR (2 of these were total occlusions) and all required repeat intervention. One patient died within 30 days of PCI.

**Conclusions:** These preliminary results show that the MGuard stent is a safe option for patients undergoing PCI in de novo coronary artery lesions in the setting of acute coronary syndrome with thrombus burden and saphenous vein graft stenosis. However the long term follow up of these patients shows significant ISR which needs to be clarified with a larger sample size.

**Keywords:** MGuard, no-reflow, distal protection

1. Director General Medicine, advisor in Cardiology Pakistan Armed Forces
2. Classified Medical Specialist / Cardiologist
3. Resident Obs/ Gynae AFIC – NIHD, Rawalpindi

Armed Forces Institute of Cardiology – National Institute of Heart Diseases, Rawalpindi.

#### Correspondence Address:

Dr. Sajjad Hussain FCPS (Cardiology), FCPS (Medicine), MRCP(UK)

Classified Medical Specialist/ Cardiologist  
Armed Forces Institute of Cardiology – National Institute of Heart Diseases Rawalpindi.

Email: sajjad.hussain.cardiologist@gmail.com  
rocking\_pegasys@hotmail.com

**INTRODUCTION**

Distal embolisation is a known peri-procedural complication of PCI, especially in acute coronary syndromes; the source of the embolism is the ruptured luminal plaque with superimposed thrombus. The trigger to the embolisation process is the mechanical trauma induced by the various devices used during PCI. In an acute coronary syndrome the embolic potential is high. This can lead to the “no-reflow phenomenon”, which is lack of intramyocardial reperfusion after successful epicardial coronary recanalization. In essence this means that although the epicardial coronary artery flow has been restored by stent placement however, there is no “myocardial blush” due to the embolisation of plaque material. Depending upon the embolus burden the consequences can vary from a simple sluggish flow to myocardial infarction and death.

Protection devices reduce distal embolisation, but add complexity and cost to the procedure. The balloon expandable MGuard stent is a unique innovation to counter the phenomenon. Its design embodies a stent covered with an ultra-thin, micron level, flexible mesh net. Once deployed the stent traps the potentially embolic material between the stent mesh and the arterial wall.

The purpose of this study was the follow up of patients in whom the MGuard Stent had been used for Percutaneous Coronary Intervention (PCI) in the setting of an acute coronary syndrome.

**MATERIALS AND METHODS**

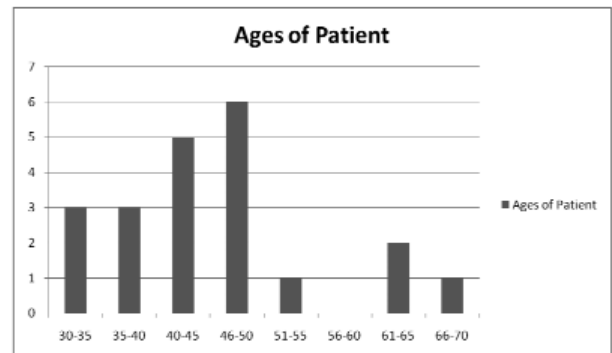
The study was conducted in AFIC – NIHD. Between April 2010 to date 21 patients were treated with a total of 25 MGuard stents. Inclusion criteria included de novo lesions in saphenous vein grafts or native vessels with angiographic evidence of thrombus activity and lesion instability with a potential for distal embolization in the setting of acute coronary syndromes. Use of filter wires or other proximal or distal protection devices was not allowed. All patients received 300 mg loading dose of clopidogrel, and 325 mg of aspirin. Necessary local ethical committee clearance was obtained. Primary end point included the incidence of MACE (composite if cardiac death,

non-fatal MI and TLR) up to 30 days after the procedure. Secondary endpoints included restoration of TIMI grade 3 flows and myocardial blush grade 3 at the end of the procedure. Clinical and angiographic follow up of these patients was conducted.

**RESULTS**

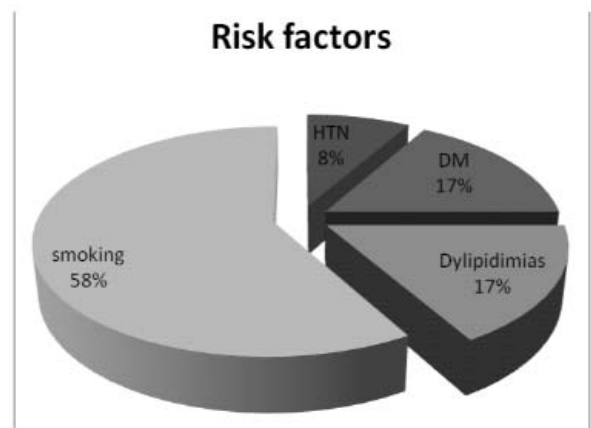
All patients were male. Mean age was 46.23 years (range 32-70 years) fig-1. 14 patients were admitted with ST elevation MI, 4 with Non-ST elevation MI, and 3 with unstable angina. 2 of the patients had previously undergone CABG. 2 vein grafts were stented while the rest were de novo lesions in native coronary arteries. Ejection fraction on echocardiography ranged from 25% to 60% (mean 40%). All the lesions where this stent was used had

**Figure-1: Age Distribution**



thrombus activity. The MGuard stent was deployed successfully in all cases and no complications of PCI including distal embolization were noted. Acute gain of vessel lumen was 100% in all cases. Cardiovascular risk factor profiles of the patients are set out in fig-2.

**Figure-2: Cardiovascular Risk Profiles of Patients**



The vessel diameter ranged from 2.5 to 3.5 mm (mean 3.0 mm). The stent length ranged from 12 to 39 mm. Secondary endpoints (TIMI – III flow and myocardial blush grade 3) were met in all cases. There was no elevation of cardiac enzymes post procedure. Follow up details are provided in the table – 1. Nine patients

**Table-1**

<b>TOTAL</b>	<b>21</b>
Angiography	12
CT angio	3
MACE	1
Loss to follow up	3
Un willing	2

(42%) had critical ISR (2 of these were total occlusions) and all required repeat intervention. Five patients had minor ISR not requiring any further intervention. Others were continued on optimised medical therapy. One patient died within 30 days of PCI. He was 47 year old, and a current smoker, with a normal lipid profile. He was admitted with an anterior STEMI and thrombolysed. His coronary angio was done as a rescue case. Angiographic findings showed an LAD eccentric lesion, and RCA & LCx ectasia. PCI to LAD was done with one MGuard (15mm 3.25mm).

## DISCUSSION

Distal embolization leading to “no-reflow” is more of a risk in the setting of acute coronary syndromes. This translates into increased adverse outcomes in terms of myocardial infarction and death.

A number of pharmacological treatments for no-reflow have been proposed. Pharmacological treatments that have been investigated include intra coronary nitroprusside<sup>1</sup>, adenosine<sup>2</sup>, verapamil<sup>3</sup>, isosorbide dinitrate<sup>4</sup> and carvedilol<sup>5</sup>. However, to date no consensus has been developed about which drug fares better than the others.

Prevention of distal embolisation using different devices has also been investigated in this regard. These device fall into different categories; distal protection devices, proximal protection devices and thrombectomy devices.


The MGuard stent is a unique innovation in the line of

protection devices in that it traps the thrombotic material at its source, i.e, at the vessel wall. The MGuard stent design embodies a balloon expandable stent covered with an ultra-thin micron level non-crease meshwork<sup>6</sup> (see fig 3). This mesh stretches over the stent it expands and forms a sleeve outside the stent that is apposed to the vessel wall. Once deployed the MGuard stent traps embolic material between the mesh and the vessel wall.

Initial studies have been performed with the MGuard stent. The First in Man study has shown promising results<sup>7</sup> when the MGuard stent system was used in twenty-nine patients with de novo coronary artery lesions and saphenous vein graft lesions with adverse characteristics. There were no MACE at 6 months of follow up. In another FIM twin centre trial<sup>8</sup> 41 patients were implanted with at least one MGuard stent. 23 patients (56%) were treated for SVG lesions and the rest for native coronary lesions. Embolic protection devices were not used during any SVG procedure. No cardiac death occurred during the 6 months follow-up. Upon further follow up and consented release of medical information between 6 and 12 months no MACE were reported. Similarly, in another study of saphenous vein graft lesions<sup>9</sup> stented with MGuard the periprocedural success rate was 100% without any no-reflow and no MACE were reported at 30 days. A case report has shown optical coherence tomographic evidence of complete plaque sealing of a large thrombus containing coronary lesion.<sup>10</sup>

**Figure-3:**

The thicker lines represent the stent struts and the thinner meshwork traps the thrombotic material.



In the INSPIRE<sup>11</sup> trial 30 patients with de novo coronary artery and vein graft lesions with features of instability and embolic potential were included. Satisfactory angiographic results without any distal embolisation or no-reflow were reported in all the patients without any MACE at 30 days. Another multicentre study<sup>12</sup> of 100 consecutive patients with ST elevation MI undergoing PCI with the MGuard stent concluded that the MGuard stent might represent a safe and feasible option for PCI in STEMI patients, providing high perfusional and ECG improvement. The authors recognized the need for further randomized trials comparing this strategy with the conventional ones to assess the impact on clinical practice of this strategy. The MGuard stent was put to a novel use in treating a large dissection of the right coronary artery in a patient with ST elevation MI on whom a primary PCI was being performed.<sup>13</sup>

ISR leading to target lesion revascularization with the Mguard stent have been cited at 19.5% at 6 months.<sup>14</sup> These ISR rates are similar to the current ISR rates in bare metal stents(BMS) of about 20-40% in different studies.<sup>15</sup> ISR can present with stable angina or in a more sinister situation as an acute coronary syndrome.<sup>16</sup>

The MGuard stent is essentially a BMS which has an extra sleeve around it. The increase in area of thrombogenic surface of the stent could be the cause of the high ISR rates. The evidence for this comes from reduction in stent strut size actually reduces the rates of ISR requiring repeat revascularization.<sup>17,18</sup>

In our study of the MGuard stent acute luminal gain was 100% without any evidence of distal embolisation. Secondary end points were achieved in all patients. No peri or post-procedural MI was documented in any of the patients. In three patients MGuard was used as a bail-out stent. One of these patients had acute stent thrombosis 36 hours after deployment of another drug eluting stent for a critical lesion in the left anterior descending artery. While the other two patients developed thrombus activity during a routine PCI for unstable angina. Our experience in the use of this stent in the vein graft patients was also uneventful. One patient suffered an acute myocardial infarction and died before 30 days.

The authors recognize the gender bias in this small sample size. The ISR rates towards the higher end could be because of the small sample size. We recognise the need for long term studies with large sample size focusing upon long term issues such as target lesion revascularization, in-stent restenosis and long term MACE. So far the preliminary data for the efficacy of the novel MGuard stent system in seem to be convincing for its indicated use.

## CONCLUSIONS

These preliminary results show that the MGuard stent is a safe option for patients undergoing PCI in de novo coronary artery lesions in the setting of acute coronary syndrome with thrombus burden and saphenous vein graft stenosis. However the long term follow up of these patients shows significant ISR which needs to be clarified with a larger sample size.

## REFERENCES

1. Niccoli G, D'Amario D, Spaziani C, Cosentino N, Marino M, Rigattieri S, et al. Randomized evaluation of intracoronary nitroprusside vs. adenosine after thrombus aspiration during primary percutaneous coronary intervention for the prevention of no-reflow in acute myocardial infarction: the REOPEN-AMI study protocol. *J Cardiovasc Med (Hagerstown)* 2009;10(7):585-92.
2. Movahed MR, Butman SM. The pathogenesis and treatment of no-reflow occurring during percutaneous coronary intervention. *Cardiovasc Revasc Med* 2008;9(1):56-61.
3. Rezkalla SH, Kloner RA. Coronary no-reflow phenomenon: from the experimental laboratory to the cardiac catheterization laboratory. *Catheter Cardiovasc Interv* 2008;72(7):950-7.
4. Tsao TP, Cheng SM, Cheng CC, Yang SP. Comparison of intracoronary adenosine and isosorbide dinitrate on no-reflow/slow flow during rotational atherectomy. *Acta Cardiol* 2009;64(2):225-30.
5. Zhao JL, Yang YJ, Pei WD, Sun YH, Zhai M, Liu YX, et al. Carvedilol reduces myocardial no-reflow by decreasing endothelin-1 via activation of the ATP-sensitive K<sup>+</sup> channel. *Perfusion*

- 2008;23(2):111-5.
6. Kaluski E, Tsai S, Klapholz M. Coronary stenting with MGuard: from conception to human trials. *Cardiovasc Revasc Med* 2008;9(2):88-94.
  7. Kaluski E, Hauptmann KE, Muller R, Tsai S, Klapholz M, Grube E. Coronary stenting with MGuard: first-in-man trial. *J Invasive Cardiol* 2008;20(10):511-5.
  8. Grube E. The Future Landscape of DES: New Stent Platforms, Drug Carriers, and Recent Experiences. In: 13th Angioplasty Summit 2008 – TCT Asia Pacific. Seoul, South Korea; 2008.
  9. Vaknin-Assa H, Assali A, Kornowski R. Preliminary experiences using the MGuard stent platform in saphenous vein graft lesions. *Catheter Cardiovasc Interv* 2009;74(7):1055-7.
  10. La Manna A, Tomasello SD, Tamburino C. Treatment of a large thrombus containing lesion with the MGuard protective net coronary stent system: optical coherence tomographic evidence of complete plaque sealing. *Clin Res Cardiol*.
  11. Maia F, Costa JR, Jr., Abizaid A, Feres F, Costa R, Staico R, et al. Preliminary results of the INSPIRE trial with the novel MGuard stent system containing a protection net to prevent distal embolization. *Catheter Cardiovasc Interv*;76(1):86-92.
  12. Piscione F, Danzi GB, Cassese S, Esposito G, Cirillo P, Galasso G, et al. Multicentre experience with MGuard net protective stent in ST-elevation myocardial infarction: safety, feasibility, and impact on myocardial reperfusion. *Catheter Cardiovasc Interv*;75(5):715-21.
  13. Rapacciuolo A, D'Andrea C, Maresca G, di Pietro E, Piscione F, Chiariello M. Multiple MGuard stent implantation to treat massive right coronary artery dissection during primary coronary angioplasty. *J Cardiovasc Med (Hagerstown)*.
  14. Grube E, Hauptmann KE, Muller R, Uriel N, Kaluski E. Coronary stenting with MGuard: extended follow-up of first human trial. *Cardiovasc Revasc Med*;12(3):138-46.
  15. Trabattoni D, Bartorelli AL. Late occlusive in-stent restenosis of a bare-metal stent presenting with ST-elevation anterior MI: is restenosis better than a late stent thrombosis? *Int J Cardiol* 2009;135(2):e65-7.
  16. Chen MS, John JM, Chew DP, Lee DS, Ellis SG, Bhatt DL. Bare metal stent restenosis is not a benign clinical entity. *Am Heart J* 2006;151(6):1260-4.
  17. Bocksch W, Pomar F, Dziarmaga M, Tresukosol D, Ismail O, Janek B, et al. Clinical safety and efficacy of a novel thin-strut cobalt-chromium coronary stent system: results of the real world Coroflex Blue Registry. *Catheter Cardiovasc Interv*;75(1):78-85.
  18. Jabara R, Geva S, Ribeiro HB, Chen JP, Hou D, Li J, et al. A third generation ultra-thin strut cobalt chromium stent: histopathological evaluation in porcine coronary arteries. *EuroIntervention* 2009;5(5):619-26.